

MOLTENO3[®]

Glaucoma Drainage Device

Surgical Guide

A Step by Step Guide to Inserting
Molteno3[®] Glaucoma Drainage Devices
for Delayed or Immediate Drainage
and either Translimbal or Pars Plana Insertion

This description should be used as a guide only and the surgeon must use his or her clinical judgement to match the surgery with the individual case.

Anthony C. B. Molteno, FRCS, FRACO

Copyright © Anthony C. B. Molteno 2006

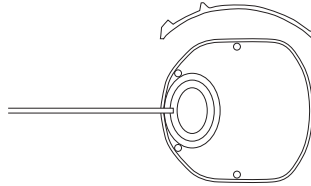
0816-SG/GDD

CE 0344

Molteno[®], Molteno3[®], M-Sphere[®] and MoaBone[®] are trade marks of Anthony C.B. Molteno,
used under licence by MOLTENO Ophthalmic Ltd.

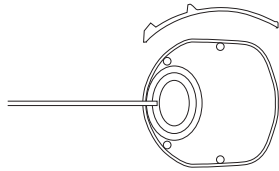
Refer to our website, www.molteno.com, for information on patents relating to our products.

GL - Single Plate 230mm²



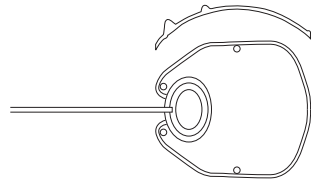
Surface Area of Plate	=	230 mm ²
Plate Thickness	=	0.4 mm
Maximum Height of Ridge	=	1.5 mm
Maximum Length	=	16 mm
Maximum Width	=	15 mm
Tube Internal Diameter	=	0.34 mm
Tube External Diameter	=	0.64 mm
Translimbal Tube Length	=	17 mm

GS - Single Plate 175mm²



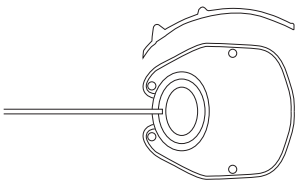
Surface Area of Plate	=	175 mm ²
Plate Thickness	=	0.4 mm
Maximum Height of Ridge	=	1.5 mm
Maximum Length	=	13.6 mm
Maximum Width	=	14.2 mm
Tube Internal Diameter	=	0.34 mm
Tube External Diameter	=	0.64 mm
Translimbal Tube Length	=	19 mm

SL - Single Plate 245mm²

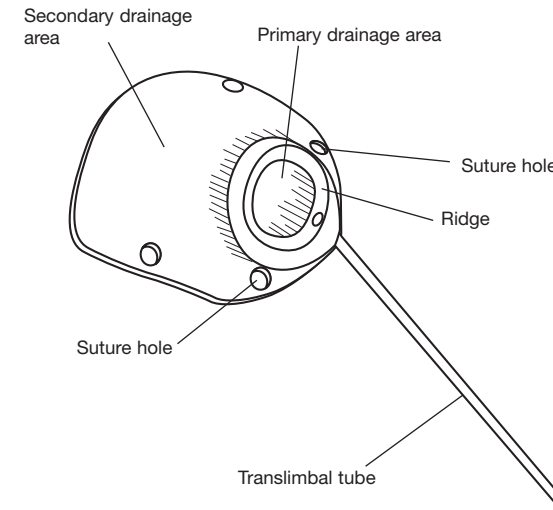


Surface Area of Plate	=	245 mm ²
Plate Thickness	=	0.4 mm
Ridge Height	=	0.95 mm
Maximum Length	=	16 mm
Maximum Width	=	15 mm
Tube Internal Diameter	=	0.34 mm
Tube External Diameter	=	0.64 mm
Translimbal Tube Length	=	17 mm

SS - Single Plate 185mm²



Surface Area of Plate	=	185 mm ²
Plate Thickness	=	0.4 mm
Ridge Height	=	0.95 mm
Maximum Length	=	13.6 mm
Maximum Width	=	14.2 mm
Tube Internal Diameter	=	0.34 mm
Tube External Diameter	=	0.64 mm
Translimbal Tube Length	=	19 mm



Molteno3® glaucoma drainage device.

TABLE OF CONTENTS

Page 2 Guidelines for the surgeon

5 Introduction

5 Surgical instruments required

6 PART 1. SURGICAL TECHNIQUE FOR TRANSLIMBAL INSERTION

6 Preparation for surgery

6 Step 1. Selecting a quadrant for the Molteno3® glaucoma drainage device

7 Step 2. The incision

8 Step 3. Fixing the position of the eye and exposing the sclera

9 Step 4. Raising a lamellar scleral flap hinged at the limbus

10 Step 5. Positioning the plate of the implant

11 Step 6. Suturing the plate of the implant in position

12 Step 7. Temporary occlusion of the translimbal tube with an absorbable suture

13 Step 7b (Optional) Temporary valve making a relieving slit in the translimbal tube: "Sherwood slit"

14 Step 8. (Optional) - For immediate drainage only. Forming a pressure sensitive 'biological valve' by stretching Tenon's tissue over the subsidiary ridge of the implant in cases where the Vicryl tie is not used

15 Step 9. Trimming the translimbal tube to the correct length

16 Step 10. Forming a channel for the tube to pass into the AC

17 Step 11. Inserting the translimbal tube into the AC

18 Step 12. Covering the tube of the implant

18 Step 12. (Optional) Covering the tube of the implant with donor sclera

19 Step 13. Closure of Tenon's tissue and the conjunctiva

20 Postoperative action of the temporary pressure sensitive 'biological valve' of the Molteno3®

21 Postoperative management

21 Long term management

22 PART 2. SURGICAL TECHNIQUE FOR THE PARS PLANA INSERTION OF THE MOLteno3®.

22 Introduction

23 Preparation for surgery

23 Step 1. Selecting a quadrant for the Molteno3®

24 Step 2. The incision

25 Step 3. Fixing the position of the eye and exposing the sclera

26 Step 4. The scleral incision

27 Step 5. Positioning the plate of the implant

28 Step 6. Placing sutures to attach the plate of the implant to the sclera

29 Step 7. Temporary occlusion of the translimbal tube with an absorbable suture "Vicryl tie"

30 Step 8. Trimming the tube to the correct length

31 Step 9. Forming a channel for the tube to pass into the posterior chamber

32 Step 10. Inserting the tube into the posterior chamber

33 Step 11. Tying the pre-placed mattress sutures to adjust the angle of the tube in the posterior chamber and to fix the plate in position on the sclera

34 Step 12. Closure of Tenon's tissue and the conjunctiva

34 Postoperative action of the temporary pressure sensitive 'biological valve' of the Molteno3®

35 Postoperative management

35 Long term management

36 Surgical steps summarised - Part 1. Surgical technique for translimbal insertion

39 Surgical steps summarised - Part 2. Surgical technique for the pars plana insertion of a Molteno3® implant.

GUIDELINES FOR THE SURGEON - PLEASE READ THIS FIRST

THE MOLTENEO3® SYSTEM: An overview of the clinical management of the process of bleb formation with insertion of a Molteno3® glaucoma drainage device

This description should be used as a guide only and the surgeon must use his or her clinical judgement to match the surgery with the individual case.

The system of management of glaucoma with all Molteno3® glaucoma drainage devices includes three important stages.

1. Preoperative management
2. Surgical procedure
3. Postoperative management

The correct management at each stage is critical for the formation of a well draining, permeable bleb capsule, which gives life long control of IOP in most cases.

1. Preoperative management.

During the preoperative period while the patient is waiting for surgery. **BRING THE PRESSURE DOWN** and **KEEP IT DOWN if at all possible until the operation.** You may need to use hypotensive medication at a level that could not be tolerated long term.

2. Surgical procedure.

USE THE VICRYL¹ TIE TECHNIQUE TO DELAY ONSET OF DRAINAGE WHEREVER POSSIBLE. This should be possible in most cases except acute conditions such as neovascular glaucoma.² The delay in the onset of drainage allows time for the tissues heal and to form a thin bleb capsule around the implant. This avoids postoperative hypotony when the Vicryl dissolves, reduces the inflammatory response which occurs at the onset of drainage and results in a more permeable bleb capsule which drains well. **The use of Mitomycin C or 5FU is not recommended** as it interferes with the formation of a healthy, permeable bleb capsule.

3. Postoperative management.

KEEP THE PRESSURE DOWN UNTIL THE ONSET OF DRAINAGE.

With the onset of drainage when the Vicryl tie dissolves and the tube opens, the IOP will fall to low normal levels initially. Stop hypotensive medication and use topical steroids to keep the eye quiet. However you should be aware that TOPICAL STEROIDS MAY CAUSE ELEVATION of IOP, when used for longer than 6 weeks in patients who are steroid responders. See Case 1.

After about 2-3 weeks the IOP will start to rise again sometimes almost to preoperative levels. DON'T PANIC! This is a normal and important stage in the process of forming a well draining bleb capsule which lasts for 5-6 weeks. It is important that the IOP should rise above the capillary pressure at this time. However if the IOP rises above 20 mmHg use beta blockers, adrenergic agents and/or carbonic anhydrase inhibitors to bring the pressure down and keep the pressure to below 20 mmHg. Often low doses are all that is required. See Case 2.

¹ 5.0 braided Vicryl, or other similar 5.0 polyglycolic acid suture will dissolve 3-5 weeks after placement within well vascularised tissue, at which time the tube will open and aqueous will flow into the preformed bleb capsule.

Vicryl is a trade mark of Ethicon Inc.

² In cases of glaucoma associated with uveitis it may be necessary to use a combination of systemic anti-inflammatory agents for several weeks after the onset of drainage to keep the eye quiet and reduce the fibrous tissue deposited in the bleb capsule.

(ref: Molteno A.C.B., Dempster A.G., *Methods of controlling bleb fibrosis around draining implants.* In K.B. Mills (ed) Glaucoma: Proceedings of the Fourth International Symposium of the Northern Eye Institute, Manchester, U.K. Pergamon Press Oxford, pp192-211, 1988.

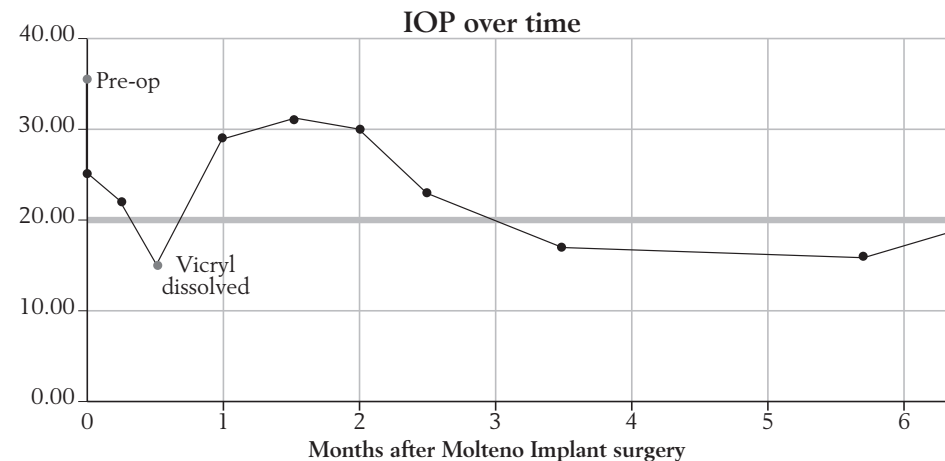
Postoperative management continued...

DO NOT USE MIOTICS OR OTHER VASODILATORS AFTER THE ONSET OF DRAINAGE as they cause elevation of IOP after glaucoma drainage surgery.

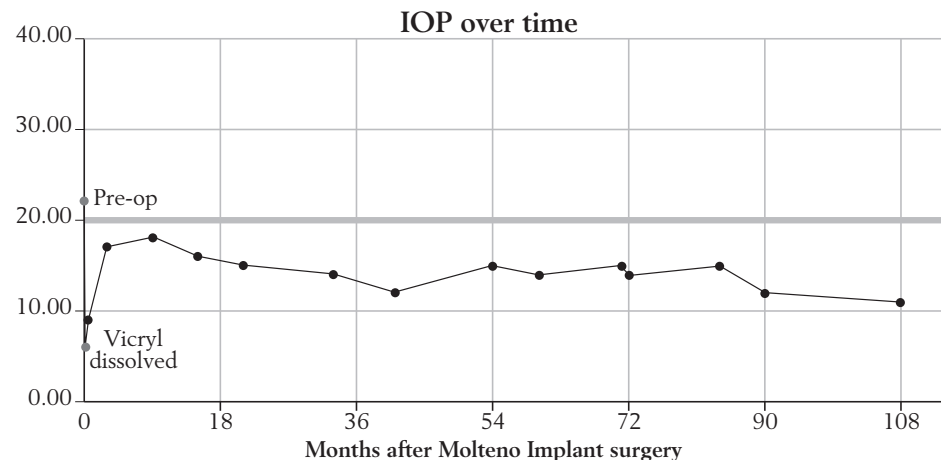
About 6-9 weeks after the onset of drainage the IOP will begin to fall, rapidly at first, and then more slowly to reach a stable level 3-6 months after the onset of drainage. If hypotensive medication has been used, it can be reduced gradually or discontinued once the IOP reaches around 15 mmHg.

4. Long term management.

KEEP THE PRESSURE DOWN below 20mmHg and ideally at between 12-16mmHg. The bleb capsule will gradually become more permeable and any need for hypotensive medication will reduce over time.



Case 2. Graph showing postoperative elevation of IOP in a 33 year old patient with ICE syndrome following a failed MMC trabeculectomy 2 months previously. After falling initially when the *Vicryl* opened the IOP rose almost to pre-op levels before being brought down to 16-17mmHg on combined medications. The IOP stabilised at around 20mmHg on timolol 12 months post-operatively.



Case 1. Graph showing the post-operative course in an 85 year old patient after a combined cataract/Molteno Implant procedure. The pre-op IOP was 22mmHg on 3 medications including acetazolamide (Diamox). A single plate Molteno Implant was used with a *Vicryl* tie for delayed drainage. Post-operatively the IOP stabilised at 11-14mmHg on no medication for the duration of follow-up.

Diamox is a trade mark of Arrow Pharmaceuticals Pty Ltd.

Guidelines for the surgeon (continued)

Selecting size of the Molteno3®?

The area needed for drainage and adequate long term control of IOP depends on the patient's age, general health and the severity of the glaucoma. In general, the greater the amount of aqueous to be drained and the stronger the patient's fibrosing response to glaucomatous aqueous the greater the area needed for drainage.

Selecting the best surgical technique - immediate or delayed drainage?

Molteno3® glaucoma drainage device may be inserted for immediate or delayed drainage. Delayed drainage is recommended wherever possible as it reduces the incidence of postoperative hypotony and gives a thinner bleb lining with superior long term control of IOP.

Delayed drainage.

Drainage of aqueous may be delayed by tying an absorbable suture such as 5.0 braided *Vicryl*, the '*Vicryl* tie', around the translimbal tube of the implant close to the plate. This allows time for the formation of a thin bleb lining, the 'preformed bleb', in the tissues around the plate. During this time the IOP is controlled by hypotensive medication supplemented, if necessary, by making a relieving slit in the side of the translimbal tube the 'Sherwood slit'. This slit acts as a safety valve and releases aqueous if the IOP rises above normal levels. It ceases to function about 4 weeks after operation around the time the *Vicryl* tie dissolves. When the *Vicryl* tie dissolves 4 to 5 weeks after operation the tube opens and aqueous drains into the 'preformed bleb' effectively preventing post-drainage hypotony.

Immediate drainage.

Immediate drainage is necessary where the eye is acutely inflamed and when immediate reduction of IOP is required. Examples include acute neovascular glaucoma or glaucoma associated with uveitis or where the eye contains blood after trauma.

This guide describes the author's current surgical technique for inserting a Molteno3® for delayed drainage which is the technique of choice for most cases. The important steps in the operation and postoperative management are described and the purpose of each step is clearly stated. It is important for the surgeon to understand the reason for each step so that he or she can adapt the technique to suit the individual case.

This description should be used as a guide only and the surgeon must use his or her clinical judgement to match the surgery with the individual case

Introduction

Molteno3® glaucoma drainage devices were developed for the treatment of severe and complex cases of glaucoma. They are now more widely used and are recommended wherever hypotensive medication or conventional drainage operation has failed or has a poor prognosis.

Indications

The Molteno® Glaucoma Drainage Devices are intended to reduce intraocular pressure in neovascular glaucoma and glaucoma where medical and conventional surgical treatments have not been successful, to control the progression of disease.

You should use Pars Plana technique when:

- the cornea is compromised or opaque,
- the anterior chamber is too shallow to permit insertion of the tube between the cornea and iris
- where a vitrectomy has been performed or is planned
- where the anterior segment of the eye is compromised so that safe translimbal drainage is doubtful.

Drainage via the posterior segment requires prior or the simultaneous performance of a vitrectomy.

When insertion of an implant is combined with other intraocular surgery it is generally best to place the implant in position on the eye and to tuck the tube out of the way by a temporary suture while the intraocular procedure is performed. This reduces the amount of handling of the soft eye after the intraocular procedure.

Surgical instruments required

Molteno3® Implant

Lid speculum

Wescott, or similar fine spring scissors

Moorfields non-toothed forceps x2

Squint hooks x2

Artery clips x2

Scalpel Plus No. 11 Bard Parker blade

Battery operated cautery

Hoskins fine non-toothed forceps

Fine needle holder

2ml syringe x3

22 gauge needle

Rycroft cannula

7.0 silk suture x1

4.0 silk suture x1

5.0 *Dexon* or *Vicryl* suture x1 (For delayed drainage only)

Blade breaker and razor blade or 30 degree diamond knife

In cases where the patient's own sclera cannot cover the tube, donor sclera or equivalent tissue

Balanced salt solution 10ml.

Subconjunctival antibiotics

Depo Medrol (methylprednisolone acetate) or equivalent

Dexon is a trade mark of Covidien AG.

PART 1. SURGICAL TECHNIQUE FOR TRANSLIMBAL INSERTION

Preparation for surgery

Your aim is to minimise bleb fibrosis around the implant so that it drains well. Glaucomatous aqueous stimulates fibrosis in the episcleral tissues resulting in a thickened bleb capsule which limits drainage. If you can manage to keep the IOP below 20mmHg for 4 to 6 weeks before surgery, a thinner bleb capsule will be formed and the final result will be much better.

Keep the IOP as low as possible prior to surgery, use maximal hypotensive medication if necessary. This may include combinations of acetazolamide, beta blocker, adrenergic agents, prostaglandin analogues or miotics in doses which could not be tolerated on a long term basis.

The operation is performed on an outpatient basis in most cases. Anaesthesia may be local or general.

Step 1.

Selecting a quadrant for the Molteno3® glaucoma drainage device

Your aim is to select the quadrant which will.

- *allow good exposure.*
- *provide an intact layer of Tenon's tissue and conjunctiva with which to cover the implant.*

The superior nasal or superior temporal quadrant are preferred. In the nasal quadrant Tenon's tissue is thicker, minimising the chance of late erosion of the tube through the conjunctiva. In addition the bleb is unobtrusive in this quadrant and subsequent cataract surgery is easier. However surgical exposure is better in the superior temporal quadrant.

If the tissues of the superior quadrants are severely damaged, the inferior quadrants may be used. Note however that diplopia can occur in patients with good vision in both eyes. The incidence of diplopia may be minimised by selecting the infero-temporal quadrant in preference to the infero-nasal quadrant and suturing the plate with its anterior edge in line with the insertions of the rectus muscles.

Neovascular glaucoma

Your aim is to preserve vision by reducing the IOP to normal levels without hypotony. Cases of acute neovascular glaucoma in particular lose vision very rapidly and should be treated as emergencies.

Reduce the IOP as far as possible in the short period between diagnosis and surgery. Use maximal hypotensive medication if necessary. This may include a combination of acetazolamide, topical beta blockers and adrenaline, in doses which could not be tolerated on a long term basis. Intravenous mannitol may be needed.

Use antibiotic drops prophylactically immediately prior to surgery.

Step 2. The incision

Your aim is to expose the sclera while carefully preserving an intact layer of Tenon's tissue and conjunctiva which will later be used to cover the implant.

Grasp the conjunctiva with a non-toothed forceps. Using a fine spring scissors, make an incision through the conjunctiva and Tenon's tissue to expose the superior nasal sclera, as follows:

Start at the inferior margin of the medial rectus muscle insertion, and extend the incision to the limbus. Then cut around the limbus to a point opposite the lateral margin of the insertion of the superior rectus. From this point cut radially back to the lateral margin of the superior rectus insertion (Fig 2).

Cauterise bleeding points.

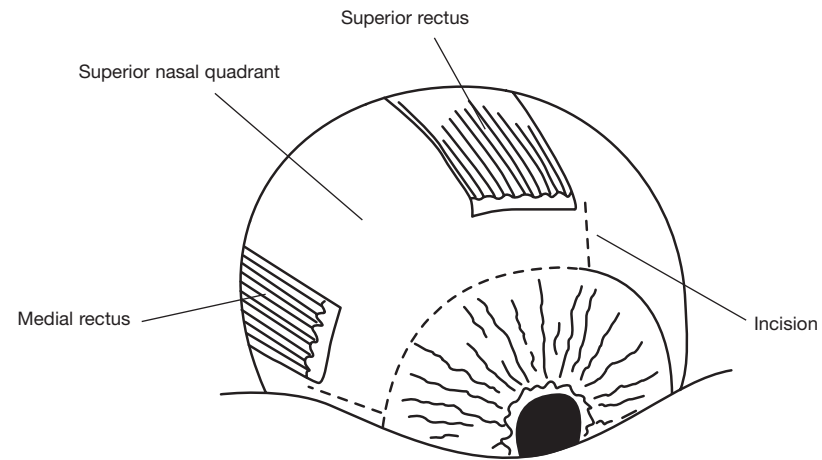


Fig. 2 The incision.
(Left eye shown as an example)

Neovascular glaucoma

In neovascular glaucoma the extraocular tissues are fragile and bleed very readily. The AC also contains abnormal blood vessels which often bleed when the tube is inserted. These factors can make the operation technically difficult. Handle the tissues very gently. Use careful haemostasis at each stage of the operation.

Carefully cauterise bleeding points.

Step 3.

Fixing the position of the eye and exposing the sclera

Your aim is to expose the insertions of the rectus muscles and the intervening sclera.

Rotate the eye downwards and laterally using two squint hooks placed under the medial or lateral and superior rectus muscle insertions (Fig 3.1).

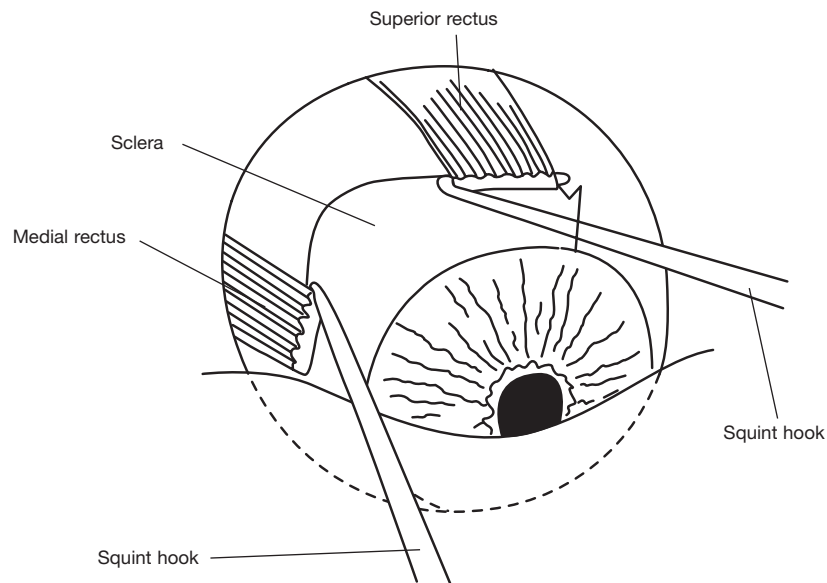


Fig. 3.1 Rotating the eye.

Fix the eye in position by passing a 4.0 silk suture under each of these rectus muscles and attach the sutures to the drapes.

Using the handle of a scalpel, gently push Tenon's tissue and the conjunctiva posteriorly, to expose the sclera for 2 to 3 mm behind the muscle insertions (Fig 3.2).

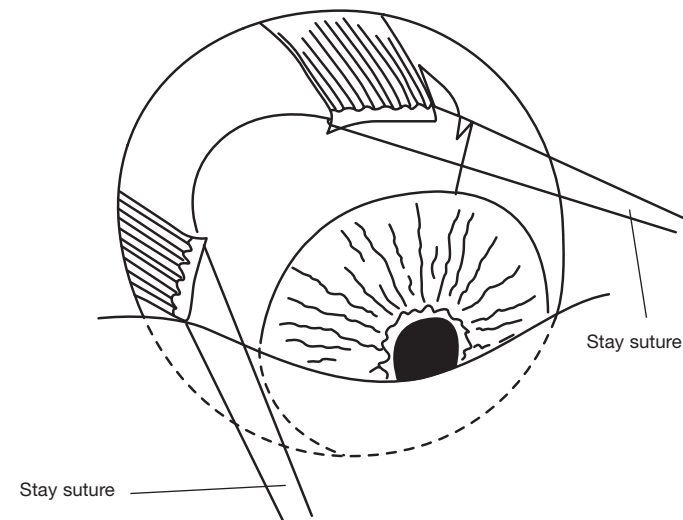


Fig. 3.2 Fixing the position of the eye.

Step 4.

Raising a lamellar scleral flap hinged at the limbus

The purpose of the flap is to:

- 1. Enable you to select the exact point at which the tube of the implant will enter the A.C.*
- 2. Provide good tissue cover for the tube.*

Note: Where the sclera is very thin, this dissection is omitted and the tube is covered by a piece of donor sclera after insertion of the tube into the A.C. (See Step 11)

Use cautery to outline three sides of a rectangular flap. The outline should extend from the limbus to a point 1 mm from the insertion of the lateral rectus muscle. From there it should pass across to a point 1 mm from the insertion of the superior rectus muscle before returning to the limbus.

Using a No. 11 Bard-Parker blade on a scalpel, make a half thickness incision through the cauterised sclera (Fig 4.1). It is important that the dissection should not be deeper than half thickness.

Using a fine Hoskins non-toothed forceps, lift the posterior corners of the flap and separate carefully from the underlying sclera using the back of a No. 11 Bard-Parker scalpel blade. Continue the dissection carefully anteriorly until it extends for 1 mm into clear cornea (Fig 4.2).

Cauterise bleeding points.

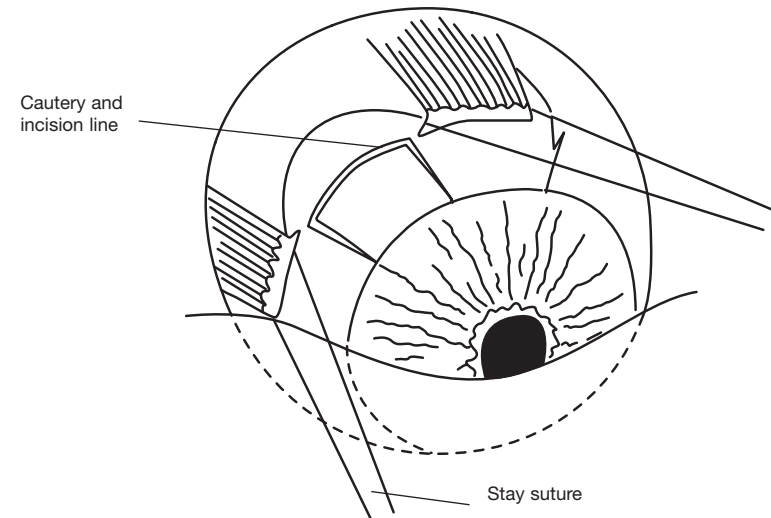


Fig. 4.1 Outlining the lamellar scleral flap.

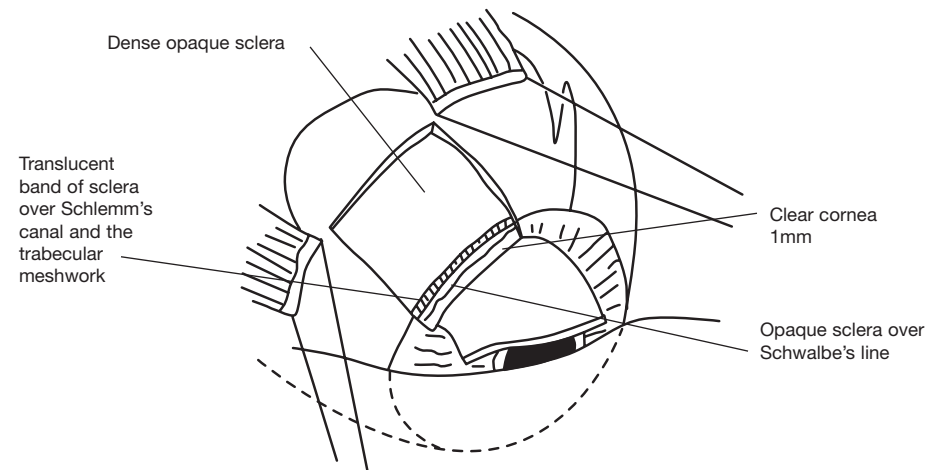


Fig. 4.2 Raising the half thickness flap and dissecting forward for 1mm into clear cornea.

Step 5.

Positioning the plate of the implant

Your aim is to position the plate of the implant so that the plate lies symmetrically between the rectus muscles. In this position interference with the action of the muscles is minimised and diplopia avoided.

Using a non-toothed Moorfield's forceps, lift Tenon's tissue and the conjunctiva away from the sclera. Then pick up the plate of the implant using another non-toothed forceps and slide the implant posteriorly into Tenon's space until the anterior edge is in line with the insertions of the rectus muscles and its drainage tube extends radially forward over the limbus (Fig 5.1). When the plate is correctly placed the suture holes lie just behind the insertions of the rectus muscles.

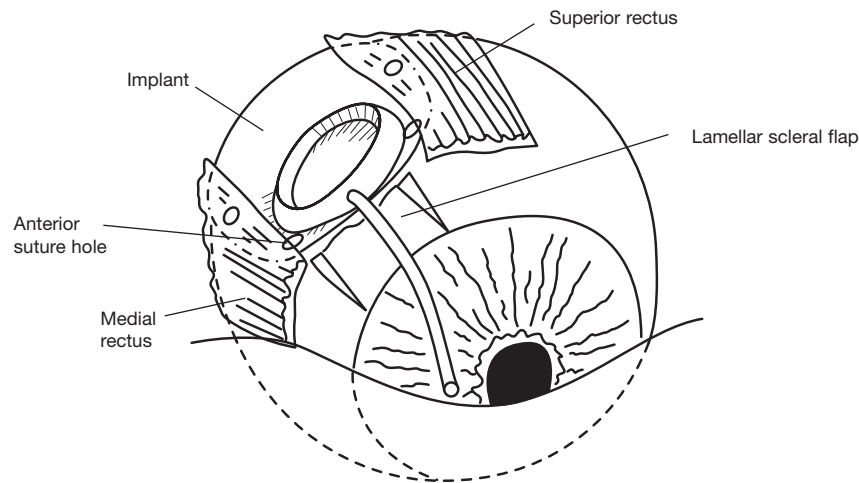


Fig. 5.1 Positioning the Molteno3® symmetrically between the muscles.

Release the plate of the implant and with non-toothed forceps carefully pull Tenon's tissue and the conjunctiva forward over the plate to the limbus. If there is any difficulty in completely covering the plate without displacing it, there is a fold of Tenon's tissue caught behind the plate. This can be freed by grasping the plate with a non-toothed forceps and wiggling it while exerting gentle forward traction on Tenon's tissue (Fig 5.2a&b).

The plate should now be lying between the rectus muscles with its anterior portion in line with the muscle insertions. The posterior part of the plate will be partly covered on either side by the rectus muscles (Fig 5.1).

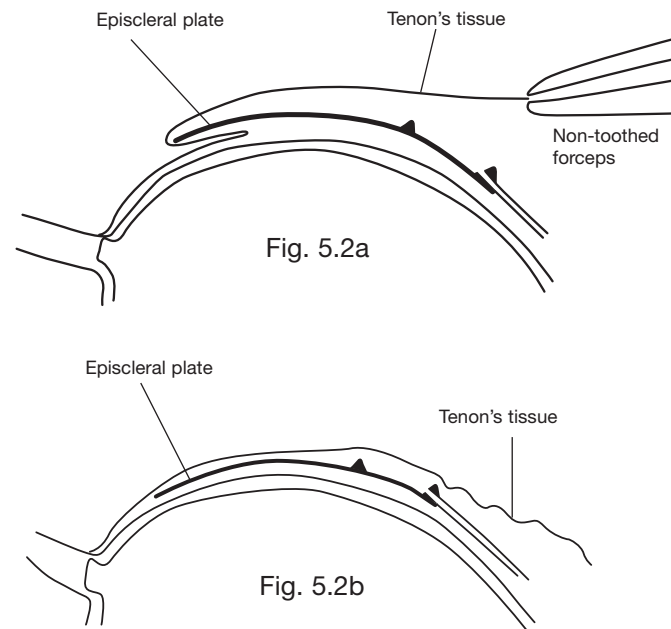


Fig. 5.2 Sectional diagram to show (5.2a) a fold of Tenon's tissue caught behind an episcleral plate and (5.2b) Tenon's tissue freed (see text)

Step 6. Suturing the plate of the implant in position

Landmarks: The implant is correctly placed when its plate lies symmetrically between the superior and medial rectus muscles. In this position the anterior two suture holes will lie just behind the insertions of the rectus muscles.

Using a non-toothed forceps, grasp the edge of the superior rectus muscle near its insertion. Using a 7.0 silk suture, pass the needle posteriorly through the sclera at the insertion of the tendon of the superior rectus muscle and for 2mm through the superficial layers of the sclera. Pass the needle from below up through the anterior suture hole in the plate. Now pass the needle forward through 1 mm of sclera and the tendon of the muscle again. (Fig 6.1) Pull the suture tight and tie a knot.

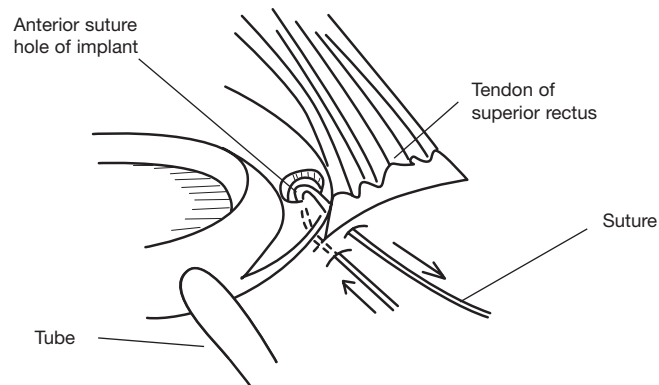


Fig. 6.1 Suturing the episcleral plate of the implant to the sclera with a mattress stitch.

Now grasp the edge of the medial rectus muscle and repeat this procedure. The plate should now be firmly fixed to the sclera just behind the rectus muscle insertions (Fig 6.2).

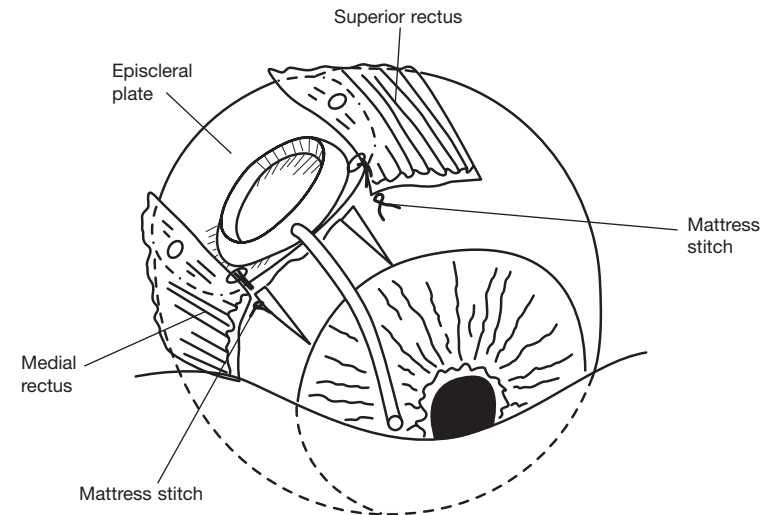


Fig. 6.2 Molteno3® sutured in position on the sclera with the episcleral plate correctly placed with its anterior edge in the line with the insertions of the rectus muscles.

Step 7.

Temporary occlusion of the translimbal tube with an absorbable suture

Temporary occlusion of the tube has two important functions.

- 1. It assists in reducing postoperative hypotony by preventing the drainage of aqueous in the immediate postoperative period.*
- 2. It allows time for a thin layer of connective tissue to develop around the plate of the implant before the tube opens and aqueous starts to drain into the bleb. The presence the preformed bleb lining gives a less fibrosed bleb capsule with correspondingly better control of IOP than is the case with immediate drainage of aqueous.*

Take a 5.0 braided polyglycolic acid suture such as *Vicryl* or *Dexon*. Carefully tie it around the tube of the implant close to the plate using two half hitches to form a slip-knot which is pulled tight and locked with a third throw. It should be tied firmly enough to block the tube (Fig 7.1). Do not use catgut as it does not absorb in this situation.

TAKE CARE when tightening the suture as it can cut through the silicone tube or pull the tube off the plate if excessive force is used.

To test that the tube has been properly occluded, take a 2ml syringe filled with saline and attach a Rycroft cannula. Insert the tip of the cannula for 3mm into the open end of the tube. Try to inject saline up the tube. If the tube has been properly occluded no saline will pass through the tube. Instead, the pressure of the saline will make the tube swell slightly and saline will flow back past the cannula.

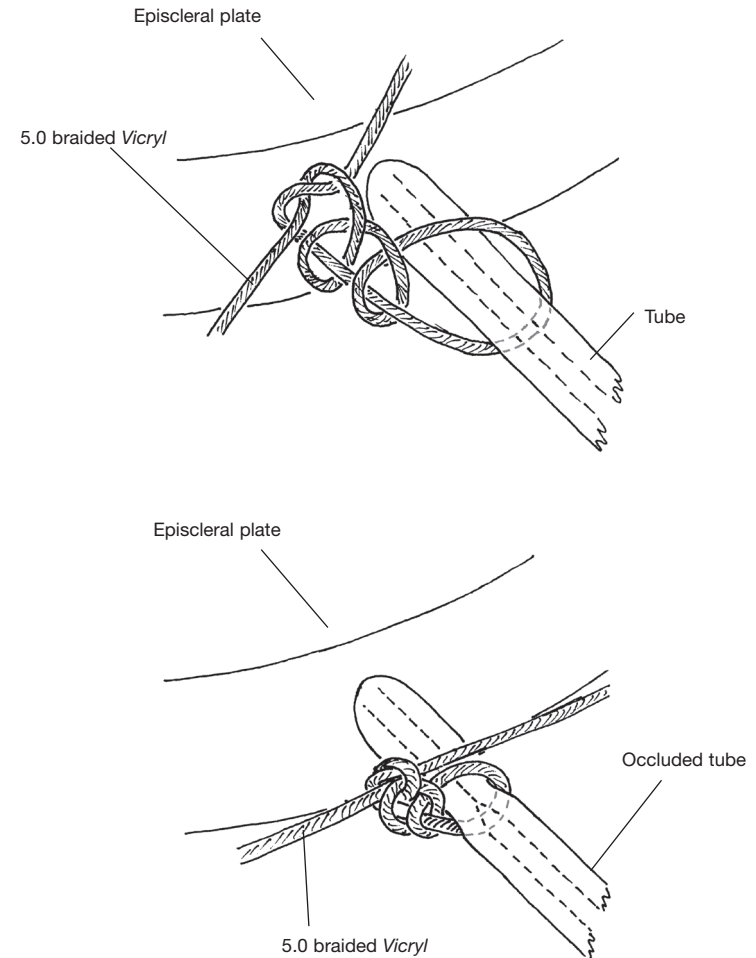


Fig. 7.1 Occluding the tube with an absorbable suture (eg 5.0 braided *Vicryl*).

Step 7b (Optional) Temporary valve

Making a relieving slit in the translimbal tube: "Sherwood slit"

The purpose of this slit is to provide temporary drainage, while the Vicryl suture is occluding the tube. The slit acts temporarily like a valve and will release aqueous if the IOP rises above normal levels. It ceases to function 3 to 4 weeks after operation, by which time the suture has dissolved and the tube has opened.

Hold the tube steady with a fine, non-toothed forceps. Take a sharp pointed razor blade fragment, or a 30 degree diamond knife, and cut a very small longitudinal slit 0.5-1 mm in length in **one side of the tube** 2-3mm below the point of occlusion (Figs 7.2 and 7.3).

Note: It is important to make the slit no more than 1mm long on the outside. The inner length will then be about 0.5mm. With these dimensions the slit will leak aqueous when the IOP reaches 15-20mmHg.

The relieving slit was first described by Dr Mark Sherwood, Gainesville, Florida. Ref: M. B. Sherwood and M. F Smith. Prevention of early hypotony associated with Molteno® implants by a new occluding stent technique. Ophthalmology 1993, 100 (1): 85 - 90

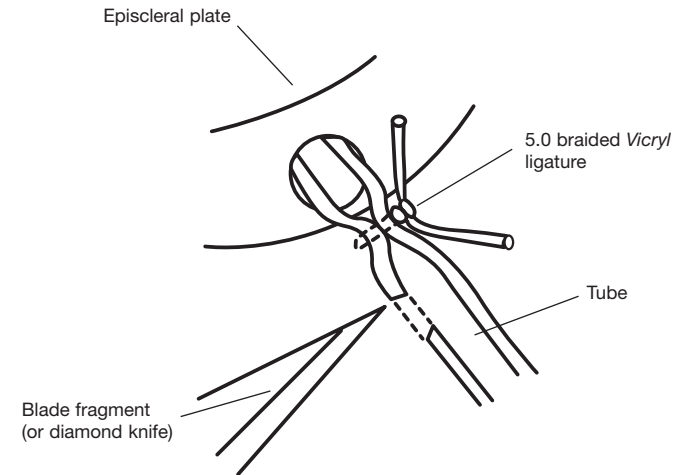


Fig. 7.2 Making a relieving slit in one wall of the tube.

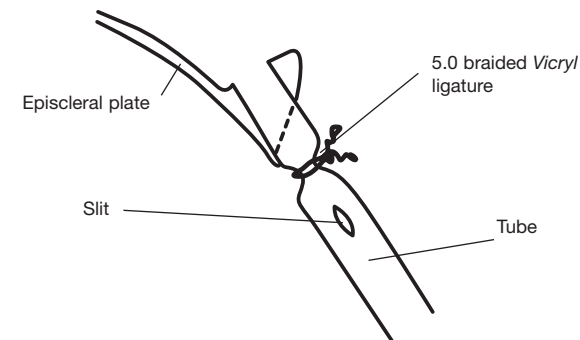


Fig. 7.3 Cross section of the episcleral plate with tube showing the slit in one wall of the tube.

Step 8. (Optional) - for immediate drainage only
Forming a pressure sensitive 'biological valve' by stretching Tenon's tissue over the subsidiary ridge of the implant in cases where the Vicryl tie is not used

Your aim is to form a pressure sensitive valve to maintain the anterior chamber during the operation and to, prevent hypotony in the early postoperative period.

The pressure-sensitive valve is formed by stretching Tenon's tissue closely over the Subsidiary Ridge of the implant and suturing it securely to the sclera. The smooth, flexible tissues of Tenon's tissue adhering closely to the subsidiary ridge of the plate acts as a pressure sensitive "biological valve". This valve system confines the aqueous to the smaller primary drainage area within the ridge until the IOP rises sufficiently to lift the tissues off the subsidiary ridge allowing aqueous to drain into the main bleb cavity.

Take a non-toothed forceps and gently pull the flap of Tenon's tissue and conjunctiva forward over the episcleral plate to the limbus (Fig. 8.1). Now lift the tissues so that you can see the undersurface of Tenon's tissue where it covers the anterior edge of the plate (Fig. 8.2).

Use a non-toothed forceps to reach under the flap and grasp the underside of Tenon's tissue at the side of the subsidiary ridge. Stretch Tenon's tissue slightly and suture it to the sclera just in front of the plate, in line with one side of the subsidiary ridge, using an interrupted 7.0 silk suture (Figs. 8.2 & 8.3). Grasp the underside of Tenon's tissue again at the other side of the subsidiary ridge. Stretch Tenon's tissue slightly and suture it to the sclera just in front of the plate and in line with that side of the subsidiary ridge. Tie both sutures firmly.

See also Stage 1: Postoperative action of the pressure sensitive valve, Pg 20.

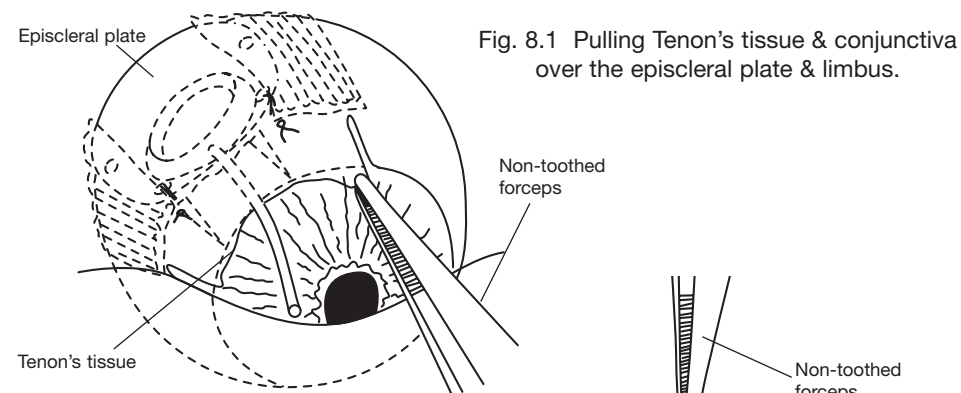


Fig. 8.1 Pulling Tenon's tissue & conjunctiva over the episcleral plate & limbus.

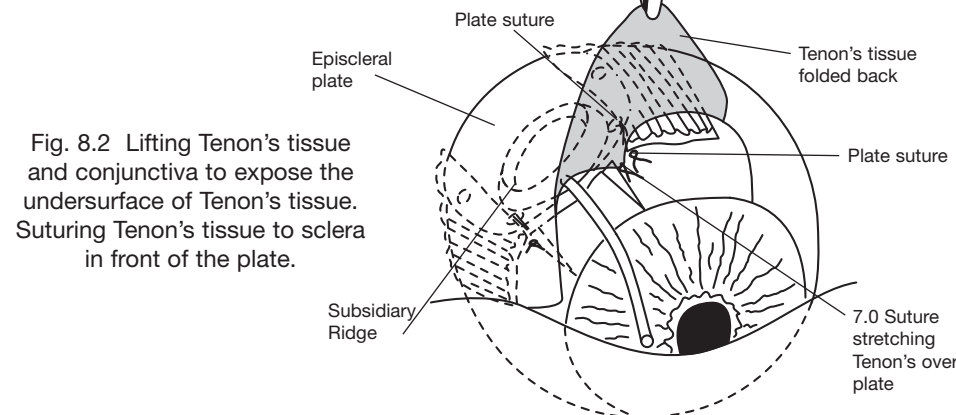


Fig. 8.2 Lifting Tenon's tissue and conjunctiva to expose the undersurface of Tenon's tissue. Suturing Tenon's tissue to sclera in front of the plate.

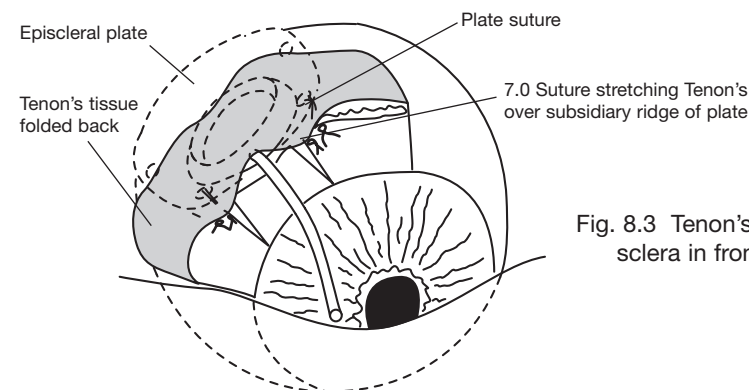


Fig. 8.3 Tenon's tissue sutured to sclera in front of the plate.

Step 9.

Trimming the translimbal tube to the correct length

Your aim is to trim the tube at 45° so that when it is inserted into the eye the bevelled tip of the tube will extend approx. 1.5 - 2mm into the AC.

The cut will be bevelled at 45° so that the open end of the tube faces forward (anteriorly). This makes it easier to insert the tube into the AC, reduces the likelihood of damage to the corneal endothelium and helps to prevent iris blocking the end of the tube.

Lift the tube of the implant and replace the lamellar scleral flap in its bed. Place the tube of the implant so that it lies over the flap and over the limbus .

Take a pair of fine spring scissors and cut the tube at an angle of 45°, so that its point overlaps the limbus by 1.5 - 2.0mm. To do this you will have to lift the tip of the tube, **taking care not to stretch it**. The cut should be at 45°, facing forward (Fig 9.1).

IMPORTANT NOTE - It is safer to cut the tube a little too long, rather than too short, as you can always cut a little more off if necessary.

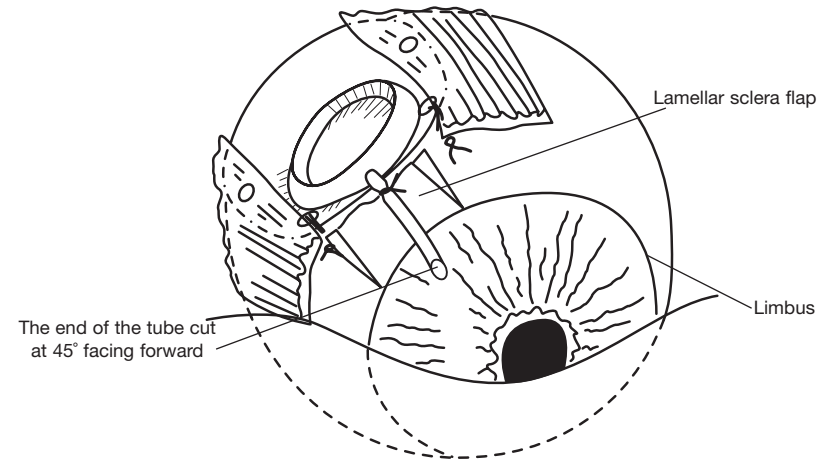


Fig. 9.1 The tube trimmed at 45 degrees so that its point overlaps the limbus by 1.5 - 2mm.

Step 10.

Forming a channel for the tube to pass into the AC

Your aim is to make a channel through firm sclera which enters the AC obliquely between the scleral spur and Schwalbe's line. This channel should be angled so that the tube lies in the plane of the iris. Firm sclera is chosen because it provides a watertight seal around the tube and holds it securely at the chosen angle.

Take a sharp 22 gauge needle on a 2ml syringe and use a needle holder to bend 3-4mm of the tip forward by 30 degrees (the bevel facing the direction of the bend) to form a microkeratome (Fig 10.1). Lift the lamellar scleral flap and fold it forward over the cornea.

Inspect the limbal region and identify:

- The dense opaque sclera over the scleral spur
- Slightly translucent tissue over the trabecular meshwork
- The opaque tissue over Schwalbe's line
- Clear cornea (Fig 10.2).

Start the track 1 mm from the posterior edge of the dense opaque sclera over the scleral spur (Figs 10.2 and 10.3). Use the tip of the needle microkeratome, holding it with its bevel facing forward, to make a track through the sclera into the AC. Extend the track by carefully pushing the tip of the needle forward keeping in the plane of the iris. It will pass through dense sclera, Schlemm's canal and trabecular tissue, and in some cases a neovascular membrane, to enter the AC at, or just in front of, the scleral spur (Fig 10.3). The microkeratome should be inserted far enough to make a tapered incision a little larger than the tube externally and a close fit internally.

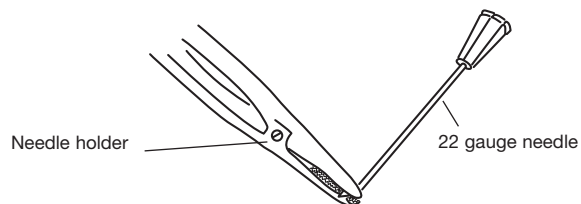


Fig. 10.1 Bending the tip of the 22 gauge needle to an angle of 30° to form a microkeratome.

Neovascular glaucoma

Some bleeding into the AC commonly occurs at this stage in cases of neovascular glaucoma. It can be controlled by injecting an air bubble into the AC to raise (maintain) the IOP. This will arrest bleeding and maintain visibility for placement of the tube.

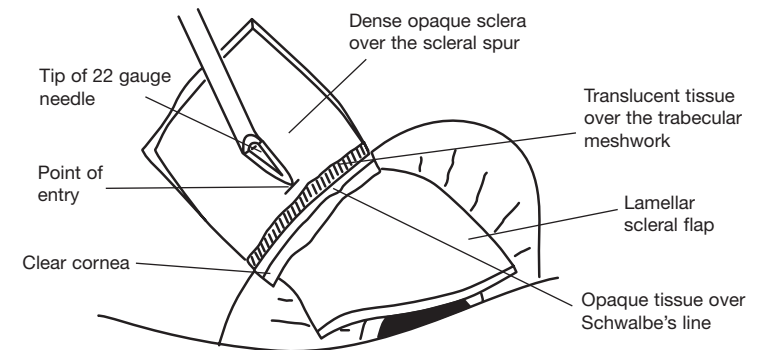


Fig. 10.2 Point of Entry through the bed of the scleral flap.

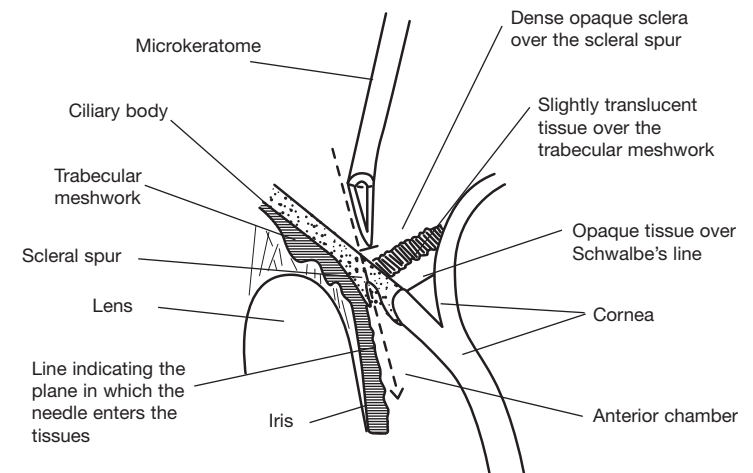


Fig. 10.3 The track of the needle through the tissues into the anterior chamber.

Step 11.

Inserting the translimbal tube into the AC

Your aim is to pass the tube through the needle track into the AC so that it lies well away from the cornea and parallel to the plane of the iris. The tube should fit snugly into the needle track so that aqueous does not leak past the tube.

Take a Rycroft cannula on a 2ml syringe, insert it into the AC through the needle track and withdraw 0.5ml aqueous from the AC. Inject a bubble of air with a Rycroft cannula to reform the AC. (This allows you to see the tube and to check that it is correctly placed after it is inserted into the eye.)

Grasp the tube with a fine non-toothed forceps and feed it carefully down the needle track (Figs 11.1 and 11.2). This may be difficult because the tubing is soft and also because the track tends to close.

If the tube won't pass into the AC, use the microkeratome again to dilate the track a little more, then pass the tube down the enlarged track.

When you have the tube in the AC, check that the position of the tube is correct. It should lie well away from the cornea and in the plane of the iris. It can touch the iris but should not dig into it. (Fig 11.2).

If the position of the tube is not correct pull it out and make a fresh track more anteriorly or posteriorly as necessary. It is not necessary to suture the old track as inserting the tube into the new track will close the old track.

Proceed to Step 12 only when you are satisfied with the position of the tube

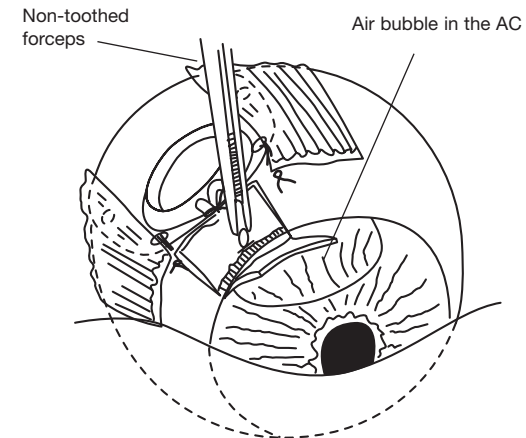


Fig. 11.1 Inserting the tube into the needle track.

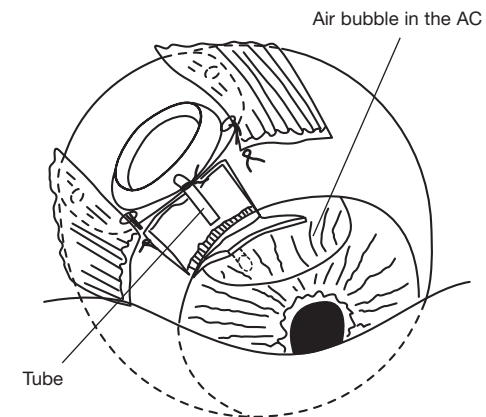


Fig. 11.2 Feeding the tube down the needle track into the AC.

Step 12.

Covering the tube of the implant

Your aim is to bury the tube deeply in scleral tissue so that it will not erode during the patient's lifetime even if the patient later develops a wasting disease such as cancer. At the same time you want the absorbable ligature occluding the tube to be exposed to vascular tissue so that it will be absorbed and the tube will open without undue delay.*

Replace the lamellar scleral flap over the tube leaving the *Vicryl* tie exposed. If necessary cut a little V-shape notch in the tissue. This ensures that the *Vicryl* tie will be exposed to vascular Tenon's tissue which breaks down the *Vicryl* and allows the tube to open about 4 weeks after operation. The lamellar scleral flap should be loosely sutured in position. Do this by using two interrupted 7.0 silk sutures, one on either side of the flap.

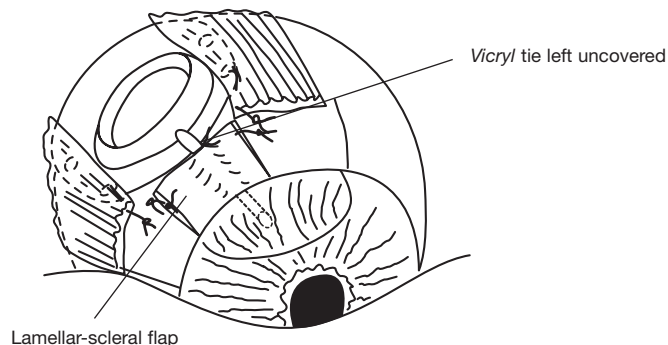


Fig. 12.1 The tube covered by the lamellar-scleral flap having the knot of the *Vicryl* tie exposed.

Footnote

*The *Vicryl* tie is usually absorbed and the tube opens about 4 weeks after operation. If necessary the *Vicryl* tie can be released with argon laser using a glass rod or a suture-lysis lens.

Step 12. (Optional)

Covering the tube of the implant with donor sclera

If the sclera is unduly thin or scarred so that the lamellar-scleral flap does not adequately cover the tube, a patch of donor sclera or equivalent tissue should be used to supplement or replace it.

To do this take a piece of donor sclera and cut a rectangle the same width as the lamellar scleral flap but 1mm shorter. Bevel its anterior edge. Cut a small V-shaped notch in the middle of the posterior edge so that the occluding suture will be exposed to vascular Tenon's tissue and conjunctiva.

Place the patch of donor sclera on top of the lamellar-scleral flap leaving 1mm between its anterior edge and the corneal epithelium. Suture the donor sclera to the patient's sclera using two interrupted sutures of 7.0 silk. These sutures should be placed 1-2mm from the anterior edge of the donor sclera (Fig 12.2).

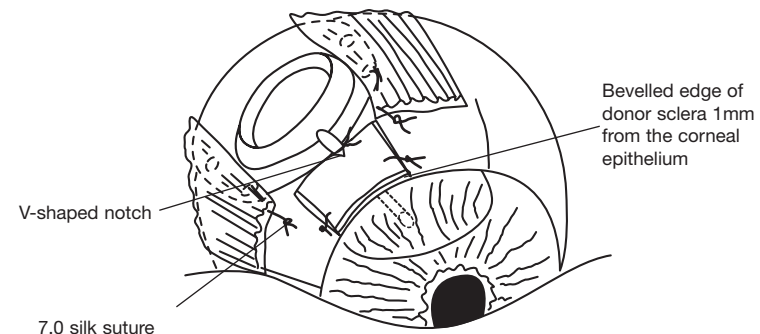


Fig. 12.2 Where donor sclera is indicated:
Reinforcing the scleral flap with donor sclera.
Note. V-shaped notch to expose the *Vicryl* tie to vascular tissue.

Step 13.

Closure of Tenon's tissue and the conjunctiva

Your aim is to cover the operative site with an intact layer of Tenon's tissue and conjunctiva.

Take a non-toothed forceps and replace Tenon's tissue and the conjunctiva so that they extend to the limbus. The tissues should lie in this position without tension. If they do not reach comfortably they have been caught up behind the plate or caught up in a stitch. Lift the tissues and carefully free them.

Suture Tenon's tissue and conjunctiva so that they completely cover the limbus using 2 or 3 interrupted sutures of 7.0 silk (Fig 13).

Inject a prophylactic antibiotic mixture such as cephalosporin and gentamicin together with a long acting steroid such as Depo Medrol, subconjunctivally, at the end of the operation.

Withhold hypotensive medication until the patient is seen on the first post operative day.

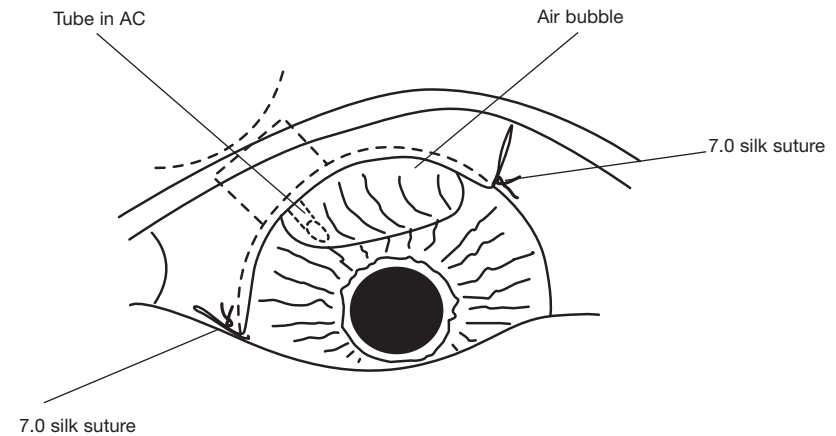


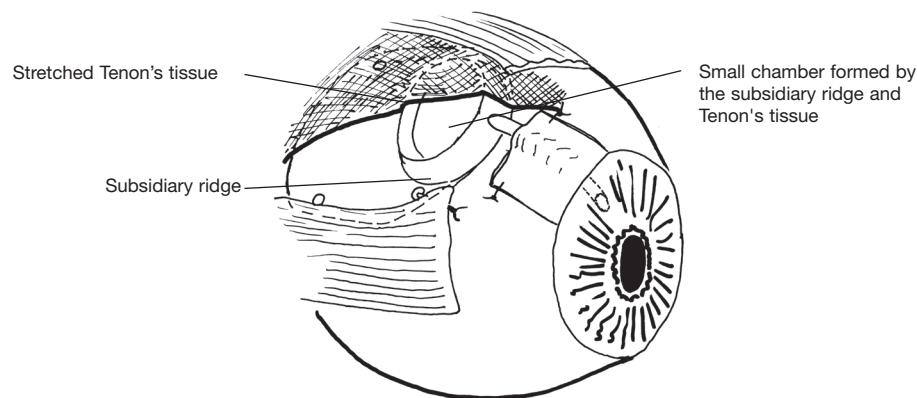
Fig. 13 The conjunctiva sutured over the limbus.

Postoperative action of the temporary pressure sensitive 'biological valve' of the Molteno3®

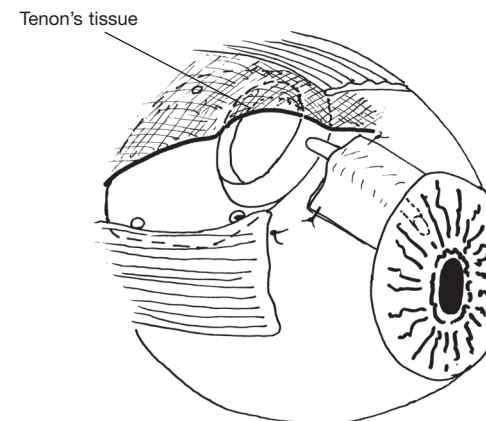
At operation Tenon's capsule is stretched over the subsidiary ridge of the Molteno3® and sutured in position. This stretched tissue forms the flexible living component of a pressure sensitive 'biological valve'.

After insertion of the tube of the implant into the AC, aqueous drains through the tube into the small chamber formed by the subsidiary ridge and Tenon's tissue which limits the escape of aqueous from the eye and prevents postoperative hypotony.

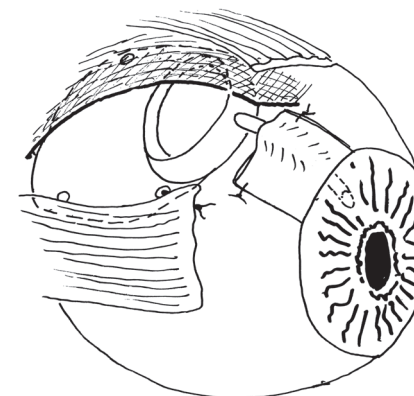
When the IOP reaches 15 to 22 mmHg the stretched Tenon's tissue lifts off the subsidiary ridge to allow a small amount of aqueous to escape into the main bleb cavity. This escape of aqueous reduces the IOP slightly, and the 'biological valve' closes until the IOP rises again and more aqueous escapes. This process continues for 14 to 21 days until sufficient aqueous accumulates in the main bleb cavity to distend it and lift the tissues off the subsidiary ridge. At this point the 'biological valve' offers no further resistance to the passage of aqueous and the prevailing level of IOP is determined by the drainage area and permeability of the fibrous bleb lining which has formed in the inner layer of Tenon's tissue.



Stage 1. One to 14 days after operation. Aqueous drains into the small chamber formed by Tenon's tissue and the subsidiary ridge of the implant prevents the escape of aqueous into the main bleb cavity.



Stage 2. Fourteen to 21 days after operation. Tenon's tissue starting to lift off the ridge



Stage 3. Tenon's tissue with its fibrous bleb lining, distended by aqueous and the 'biological valve' no longer active.

Postoperative management

See the patient the day after surgery. Examine the eye. Give topical steroids as a routine. If there is anterior chamber reaction, cycloplegic agents may be added. Measure the IOP. Adjust the hypotensive medication to keep the IOP within the 10-20mmHg range.

When the bleb becomes distended, immediately stop any miotics or prostaglandin analogues that are being used. (Distention occurs 3 to 5 weeks postoperatively in cases where the delayed drainage technique has been used, and shortly after surgery in cases where the immediate drainage technique has been used.

Miotics and prostaglandin analogues frequently increase the IOP in the presence of a draining bleb and should not be used after the onset of drainage.

See the patient weekly for 3 to 5 weeks after operation.

Monitor the IOP. Keep the pressure below 20mmHg. If necessary give acetazolamide, topical beta-blockers and topical epinephrine 1-2% or equivalent adrenergic drops. To ensure that the eye remains quiet and to minimise bleb fibrosis, give topical steroids for 4 weeks after onset of drainage.

Caution: Topical steroids should be used with caution beyond this time as use for more than a few weeks occasionally causes elevation of IOP despite the presence of a draining bleb.

In cases of Neovascular glaucoma:

Photocoagulation of the underlying retinal condition should be started as soon as the media clear sufficiently. Patients who have the potential for useful vision may benefit from the oral administration of a combination of prednisone, diclofenac and colchicine for four to six weeks after operation. This will promote rapid clearing of the media and reduce the amount of fibrous tissue in the bleb.

A vitally important part of management is the careful medical control of the diabetes or cardiovascular disease that is almost always present in these cases.

Long term management

Once the situation has stabilised, see the patient three monthly for the first year, six monthly for the next two years and then annually.

Use hypotensive medication if necessary to keep the IOP well under control. Patients who require hypotensive medication after insertion of the Molteno3® should be encouraged to take their medication to keep their IOP below 20mmHg and ideally between 12 and 16mmHg. Over the long term this will result in improved bleb function and eventual control of IOP without medication in most cases. A very low dose of acetazolamide (eg. 60mg, twice a day) is often all that is needed to reduce the IOP to a low normal range. Other effective hypotensive agents are topical beta blockers eg timolol, topical or systemic carbonic anhydrase inhibitors eg acetazolamide and topical adrenergic agents eg epinephrine, these may be used singly or in combination.

PART 2. SURGICAL TECHNIQUE FOR THE PARS PLANA INSERTION OF THE MOLTEÑO3®.

Introduction

The surgical technique recommended for pars plana insertion is a modification of that used for translimbal insertion. Pars plana insertion is indicated where

- the cornea is compromised or opaque,
- the anterior chamber is too shallow to permit insertion of the tube between the cornea and iris
- where a vitrectomy has been performed or is planned
- where the anterior segment of the eye is compromised so that safe translimbal drainage is doubtful.

Drainage via the posterior segment requires prior or the simultaneous performance of a vitrectomy. In addition, other intraocular procedures such as cataract extraction or keratoplasty may need to be performed at the same time.

When insertion of an implant is combined with other intraocular surgery it is best to place the implant in position on the eye (steps 1-8 below) and to tuck the tube out of the way by a temporary suture while the intraocular procedure is performed.

Inserting the tube into the eye should be delayed until after completion of the associated intraocular procedure.

Preparation for surgery

Your aim is to minimise bleb fibrosis around the implant so that it drains well. Glaucomatous aqueous stimulates fibrosis in the episcleral tissues resulting in a thickened bleb capsule which limits drainage. If you can manage to keep the IOP below 20mmHg for 4 to 6 weeks before surgery, a thinner bleb capsule will be formed and the final result will be much better.

Keep the IOP as low as possible prior to surgery, use maximal hypotensive medication if necessary. This may include combinations of acetazolamide, beta blocker, adrenergic agents, prostaglandin analogues or miotics in doses which could not be tolerated on a long term basis.

The operation is performed on an outpatient basis in most cases. Anaesthesia may be local or general.

Step 1.

Selecting a quadrant for the Molteno3®

Your aim is to select the quadrant which will.

- *allow good exposure.*
- *provide an intact layer of Tenon's tissue and conjunctiva with which to cover the implant.*

The superior nasal or superior temporal quadrant are preferred. In the nasal quadrant Tenon's tissue is thicker, minimising the chance of late erosion of the tube through the conjunctiva. In addition the bleb is unobtrusive in this quadrant and subsequent cataract surgery is easier. However surgical exposure is better in the superior temporal quadrant.

If the tissues of the superior quadrants are severely damaged, the inferior quadrants may be used. Note however that diplopia can occur in patients with good vision in both eyes. The incidence of diplopia may be minimised by selecting the infero-temporal quadrant in preference to the infero-nasal quadrant and suturing the plate with its anterior edge in line with the insertions of the rectus muscles.

Step 2. The incision

Your aim is to expose the sclera while carefully preserving an intact layer of Tenon's tissue and conjunctiva which will later be used to cover the implant.

Grasp the conjunctiva with a non-toothed forceps. Using a fine spring scissors, make an incision through the conjunctiva and Tenon's tissue to expose the superior nasal sclera, as follows:

Start at the inferior margin of the medial rectus muscle insertion, and extend the incision to the limbus. Then cut around the limbus to a point opposite the lateral margin of the insertion of the superior rectus. From this point cut radially back to the lateral margin of the superior rectus insertion (Fig 2).

Cauterise bleeding points.

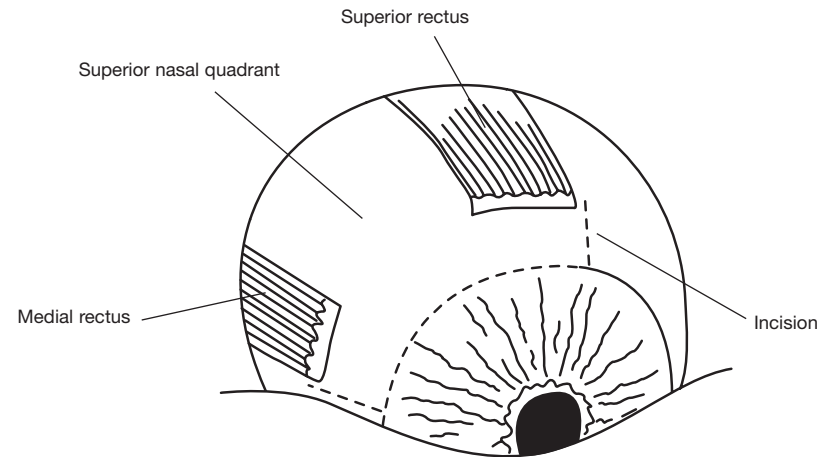


Fig. 2 The incision.
(Left eye shown as an example)

Step 3.

Fixing the position of the eye and exposing the sclera

Your aim is to expose the insertions of the rectus muscles and the intervening sclera.

Rotate the eye downwards and laterally using two squint hooks placed under the medial or lateral and superior rectus muscle insertions (Fig 3.1).

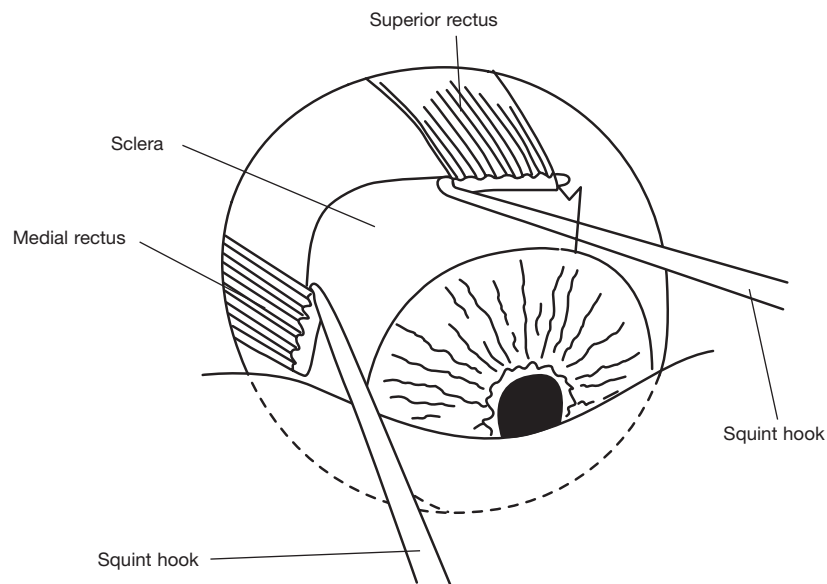


Fig. 3.1 Rotating the eye.

Fix the eye in position by passing a 4.0 silk suture under each of these rectus muscles and attach the sutures to the drapes.

Using the handle of a scalpel, gently push Tenon's tissue and the conjunctiva posteriorly, to expose the sclera for 2 to 3 mm behind the muscle insertions (Fig 3.2).

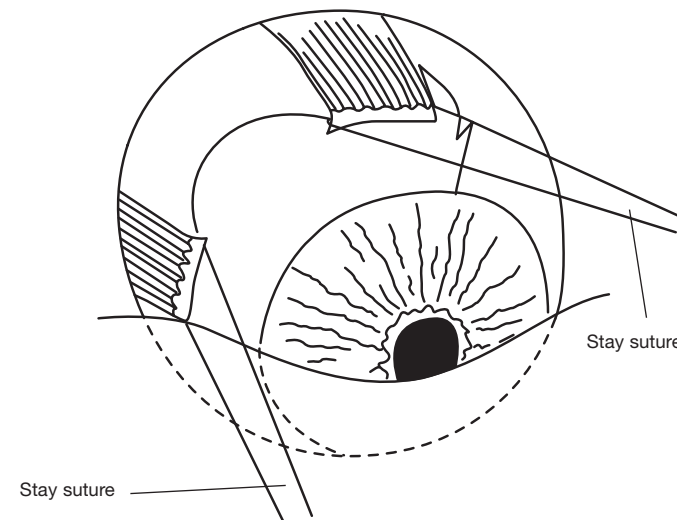


Fig. 3.2 Fixing the position of the eye.

Step 4.

The scleral incision

Your aim is to make a partial thickness incision through the sclera at a point midway between and level with the rectus muscle insertions.

Use a No. 15 surgical blade to make a 3 to 4 mm partial thickness incision parallel to the limbus. Cauterise the edges of the wound and deepen the incision until you are approaching the underlying choroid. Cauterise the bed of the incision thoroughly to coagulate underlying choroid blood vessels.

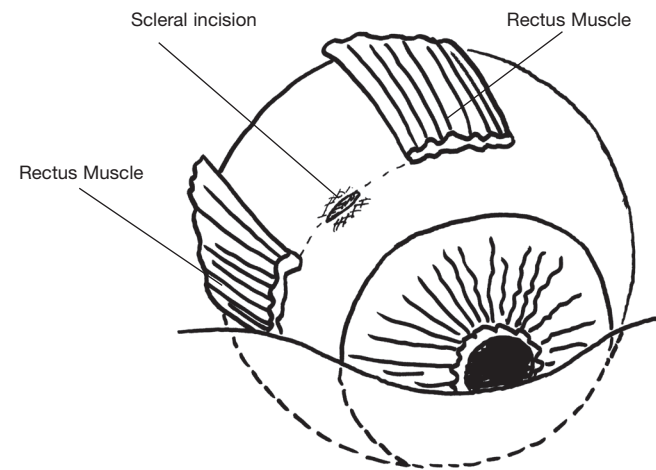


Fig. 4 Position of partial thickness scleral incision parallel to limbus.

Step 5.

Positioning the plate of the implant

Your aim is to position the plate of the implant so that the plate lies symmetrically between the rectus muscles. In this position interference with the action of the muscles is minimised and diplopia avoided.

Using a non-toothed Moorfield's forceps, lift Tenon's tissue and the conjunctiva away from the sclera. Then pick up the plate of the implant using another non-toothed forceps and slide the implant posteriorly into Tenon's space until the anterior edge is in line with the insertions of the rectus muscles and its drainage tube extends radially forward over the limbus (Fig 5.1). When the plate is correctly placed the suture holes lie just behind the insertions of the rectus muscles.

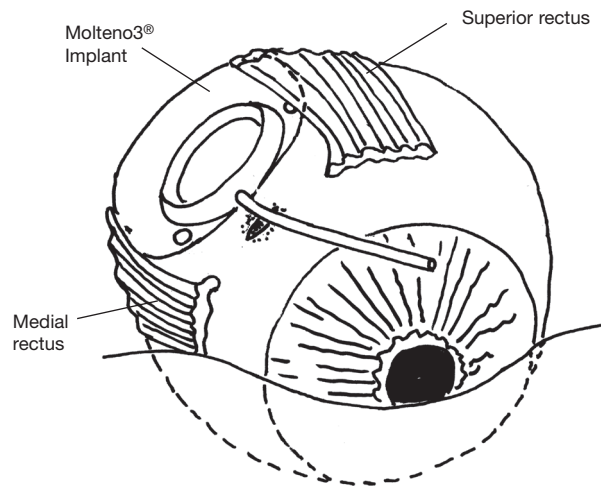


Fig. 5.1 Positioning the Molteno3® symmetrically between the muscles.

Release the plate of the implant and with non-toothed forceps carefully pull Tenon's tissue and the conjunctiva forward over the plate to the limbus. If there is any difficulty in completely covering the plate without displacing it, there is a fold of Tenon's tissue caught behind the plate. This can be freed by grasping the plate with a non-toothed forceps and wiggling it while exerting gentle forward traction on Tenon's tissue (Fig 5.2).

The plate should now be lying between the rectus muscles with its anterior edge just behind the muscle insertions (Fig 5.2).

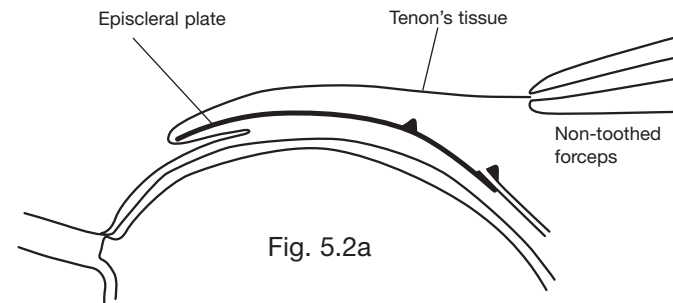


Fig. 5.2a

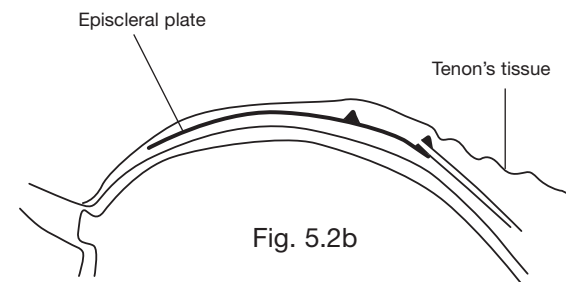


Fig. 5.2b

Fig. 5.2 Sectional diagram to show (5.2a) a fold of Tenon's tissue caught behind an episcleral plate and (5.2b) Tenon's tissue freed (see text)

Step 6.

Placing sutures to attach the plate of the Molteno3® to the sclera leaving them untied

Your aim is to place the sutures leaving them untied until late in the procedure. This facilitates insertion of the tube into the posterior chamber.

Landmarks: The Molteno3® is correctly placed when its plate lies symmetrically between the superior and medial rectus muscles. In this position the anterior two suture holes will lie just behind the insertions of the rectus muscles.

Using a non-toothed forceps, grasp the edge of the superior rectus muscle near its insertion. Using a 7.0 silk suture, pass the needle posteriorly through the sclera at the insertion of the tendon of the superior rectus muscle and for 2mm through the superficial layers of the sclera. Pass the needle from below up through the anterior suture hole in the plate. Now pass the needle forward through 1 mm of sclera and the tendon of the muscle again. Place another suture in the same manner through the sclera at the insertion of the tendon of the medial rectus muscle. (Fig 6)

Leave the sutures loose and do not tie the knots at this stage. The plate should now be loosely attached to the sclera several millimeters behind the scleral incision

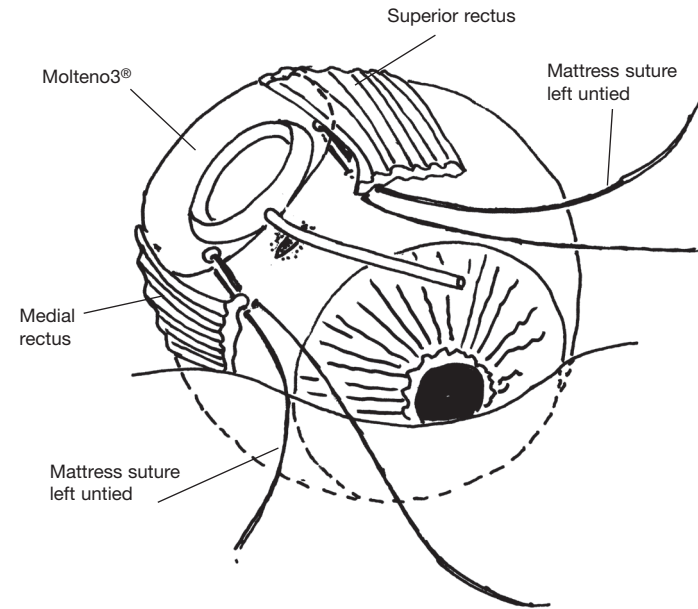


Fig. 6 Molteno3® positioned on the sclera between the rectus muscles with sutures placed but not tied.

Step 7.

Temporary occlusion of the translimbal tube with an absorbable suture "Vicryl tie"

Temporary occlusion of the tube has two important functions.

- 1. It assists in preventing postoperative hypotony by reducing the drainage of aqueous in the immediate postoperative period.*
- 2. It allows time for a thin layer of connective tissue to develop around the plate of the implant before the tube opens and aqueous starts to drain into the bleb. The presence of the preformed bleb lining gives a less fibrosed bleb capsule with correspondingly better control of IOP than is the case with immediate drainage of aqueous.*

Take a 5.0 braided polyglycolic acid suture such as *Vicryl* or *Dexon*. Carefully tie it around the tube of the implant close to the plate using two half hitches to form a slip-knot which is pulled tight and locked with a third throw. It should be tied firmly enough to block the tube (Fig 7). Do not use catgut as it does not absorb in this situation.

TAKE CARE when tightening the suture as it can cut through the silicone tube or pull the tube off the plate if excessive force is used.

To test that the tube has been properly occluded, take a 2ml syringe filled with saline and attach a Rycroft cannula. Insert the tip of the cannula for 3mm into the open end of the tube. Try to inject saline up the tube. If the tube has been properly occluded no saline will pass through the tube. Instead, the pressure of the saline will make the tube swell slightly and saline will flow back past the cannula.

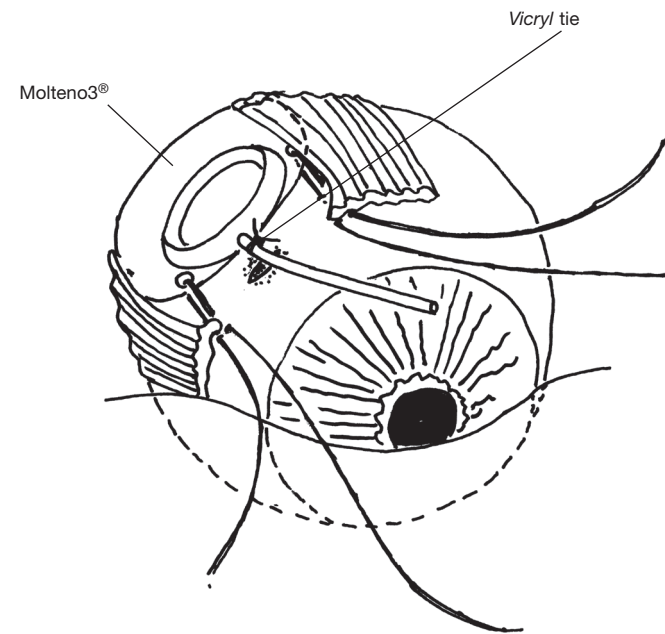


Fig. 7 Occluding the tube with an absorbable suture (eg 5.0 braided *Vicryl*) close to the plate of the implant.

Step 8.

Trimming the tube to the correct length

Your aim is to trim the tube so that when it is inserted into the eye through the opening you have made in the sclera its open end will lie just outside the visual axis but visible through a dilated pupil.

The correct length of the tube will usually be between 5 and 8 mm depending on the size of the eye, longer for unusually large eyes. Make the tube long enough so that its tip can be seen through the dilated pupil. This has the advantage that, if it should become blocked by remnants of vitreous they can be easily dislodged by means of a Yag laser. Cut the tip of the tube off at a bevel of 45 degrees facing forward.

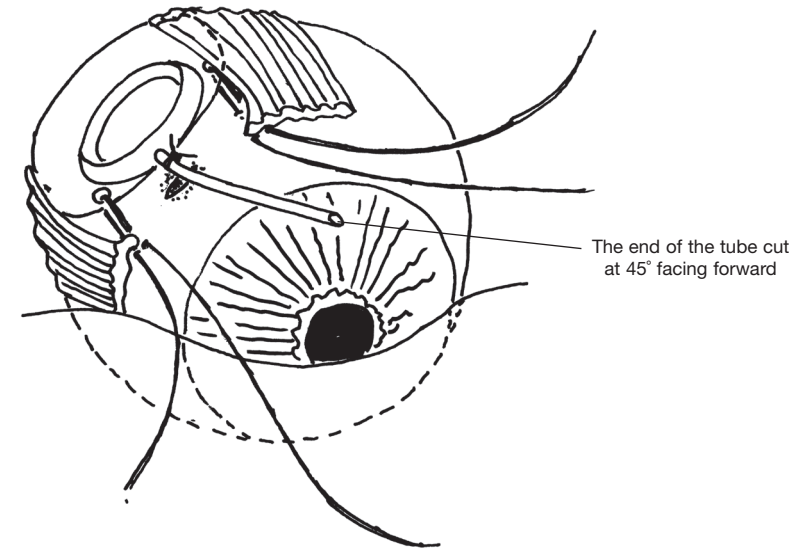


Fig. 8 The tube trimmed at 45 degrees so that its point facing forward 5-8mm from the plate.

Step 9.

Forming a channel for the tube to pass into the posterior chamber

Your aim is to insert the tube into the posterior chamber through a watertight incision in the sclera made with a custom-made microkeratome.

To make a microkeratome take a sharp 22 gauge needle and, using a needle holder, bend 3-4 mm of the tip forward by 30 degrees, the bevel facing the direction of the bend (Fig 9.1).

Complete the incision through the pars plana by inserting the tip of the microkeratome blade vertically through the bed of the incision and into the posterior chamber. The microkeratome should be inserted far enough to make a tapered channel a little larger than the tube externally and a close fit internally (Fig 9.2).

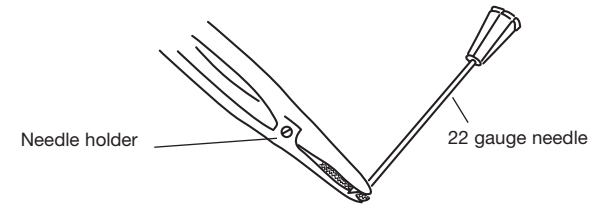


Fig. 9.1 Bending the tip of the 22 gauge needle to an angle of 30° to form a microkeratome.

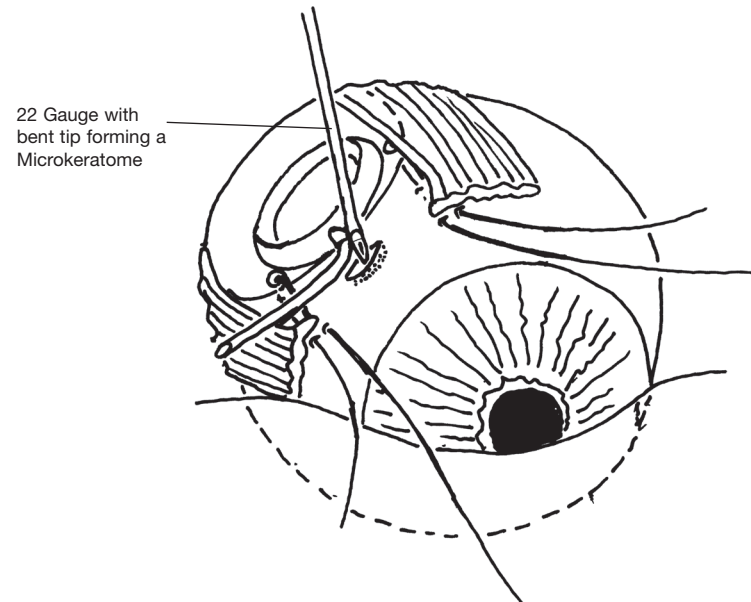


Fig. 9.2 Forming a channel for the tube to pass into the posterior chamber.

Step 10.

Inserting the tube into the posterior chamber

Grasp the tube about 2mm behind the tip with a non-toothed forceps and insert the bevelled end of the tube vertically into the posterior chamber through the incision (Fig 10.1). If the incision is too small insert the microkeratome again, a little further this time, to enlarge the incision.

Feed the full length of the tube into the posterior chamber. Observe the position of the tip through the pupil to ensure that it is correctly positioned in the posterior chamber (Fig 10.2 and 10.3). Make sure that the tube has not come to lie in the suprachoroidal space! Correct the position of the tube if necessary

If it is necessary to clear vitreous from the region of the tip of the tube, the scleral incision can be widened to allow insertion of a vitrector. In this case the scleral incision should be carefully sutured to prevent leakage around the tube.

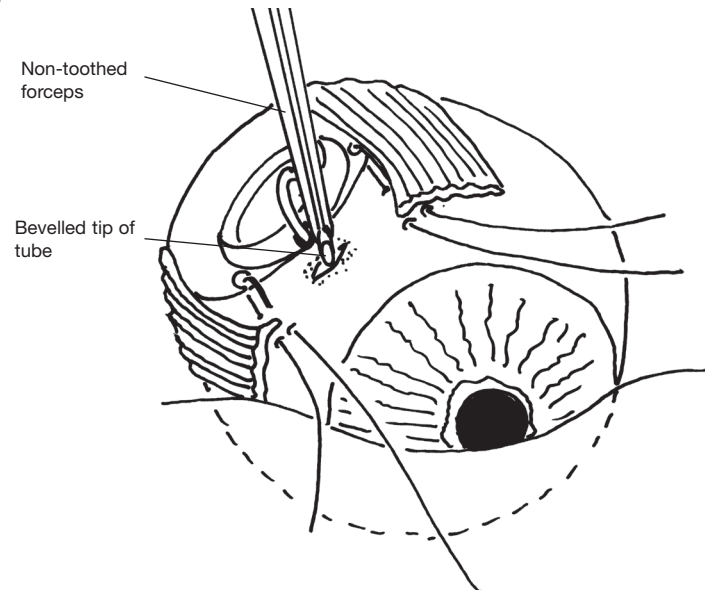


Fig. 10.1 Inserting the tube into the posterior chamber.

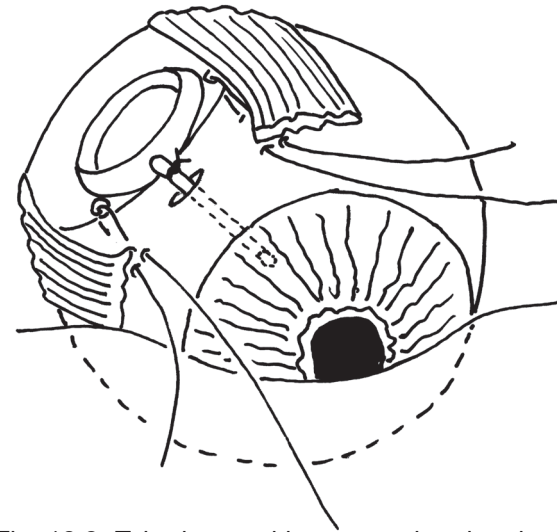


Fig. 10.2 Tube inserted into posterior chamber.

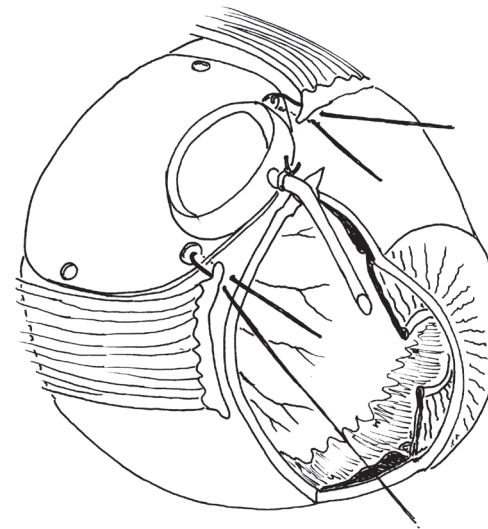


Fig. 10.3 Position of tube in posterior chamber before tying sutures.

Step 11.

Tying the pre-placed mattress sutures to adjust the angle of the tube in the posterior chamber and to fix the plate in position on the sclera.

Your aim is to bring the plate of the implant forward so as to adjust the angle at which the tube passes through the sclera and, consequently, the angle at which the tube lies in the posterior chamber.

Put a double throw on each of the pre-placed mattress sutures holding the plate. Now tighten these gradually to shift the plate forward and adjust the angle at which the tube passes through the sclera. Ideally, the tube will pass through the sclera at an angle of about 45-50 degrees so that it lies parallel to the plane of the iris. (Figs 11.1 and 11.2).

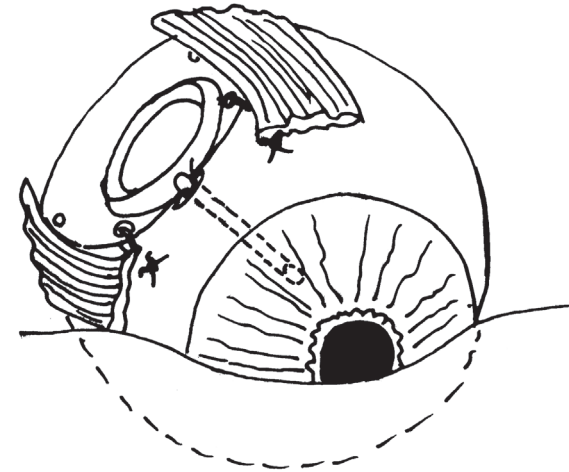


Fig. 11.1 Tube in posterior chamber after tying sutures.

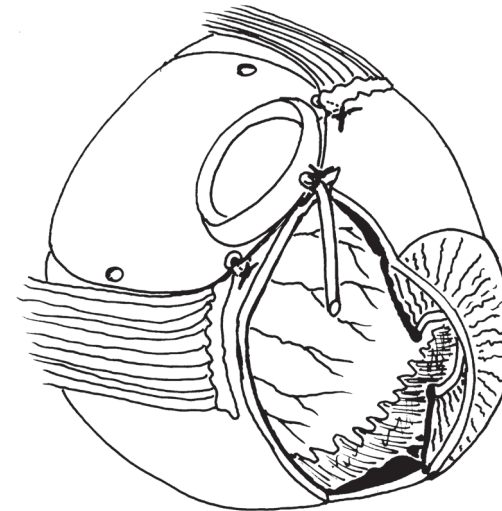


Fig. 11.2 Position of tube in posterior chamber after tying sutures.

Step 12.

Closure of tenon's tissue and the conjunctiva

Your aim is to cover the operative site with an intact layer of Tenon's tissue and conjunctiva.

Take a non-toothed forceps and replace Tenon's tissue and the conjunctiva so that they extend to the limbus. The tissues should lie in this position without tension. If they do not reach comfortably they have been caught up behind the plate or caught up in a stitch. Lift the tissues and carefully free them.

Suture Tenon's tissue and conjunctiva so that they completely cover the limbus using 2 or 3 interrupted sutures of 7.0 silk (Fig 13).

Inject a prophylactic antibiotic mixture such as cephalosporin and gentamicin together with a long acting steroid such as Depo Medrol, subconjunctivally, at the end of the operation.

Withhold hypotensive medication until the patient is seen on the first post operative day.

Postoperative action of the temporary pressure sensitive 'biological valve' of the Molteno3® - see page 20

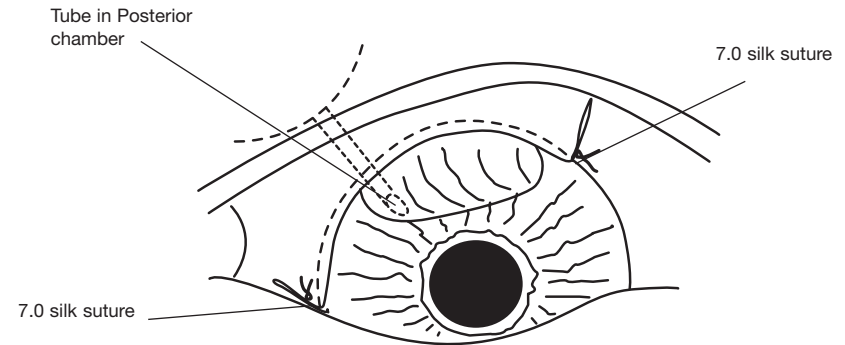


Fig. 12 The conjunctiva sutured over the limbus.

Postoperative management

See the patient the day after surgery. Examine the eye. Give topical steroids as a routine. If there is anterior chamber reaction, cycloplegic agents may be added. Measure the IOP. Adjust the hypotensive medication to keep the IOP within the 10-20mmHg range.

When the bleb becomes distended, immediately stop any miotics or prostaglandin analogues that are being used. (Distention occurs 3 to 5 weeks postoperatively in cases where the delayed drainage technique has been used, and shortly after surgery in cases where the immediate drainage technique has been used.

Miotics and prostaglandin analogues frequently increase the IOP in the presence of a draining bleb and should not be used after the onset of drainage.

See the patient weekly for 3 to 5 weeks after operation.

Monitor the IOP. Keep the pressure below 20mmHg. If necessary give acetazolamide, topical beta-blockers and topical epinephrine 1-2% or equivalent adrenergic drops. To ensure that the eye remains quiet and to minimise bleb fibrosis, give topical steroids for 4 weeks after onset of drainage.

Caution: Topical steroids should be used with caution beyond this time as use for more than a few weeks occasionally causes elevation of IOP despite the presence of a draining bleb.

In cases of Neovascular glaucoma:

Photocoagulation of the underlying retinal condition should be started as soon as the media clear sufficiently. Patients who have the potential for useful vision may benefit from the oral administration of a combination of prednisone, diclofenac and colchicine for four to six weeks after operation. This will promote rapid clearing of the media and reduce the amount of fibrous tissue in the bleb.

A vitally important part of management is the careful medical control of the diabetes or cardiovascular disease that is almost always present in these cases.

Long term management

Once the situation has stabilised, see the patient three monthly for the first year, six monthly for the next two years and then annually.

Use hypotensive medication if necessary to keep the IOP well under control. Patients who require hypotensive medication after insertion of a Molteno3® should be encouraged to take their medication to keep their IOP below 20mmHg and ideally between 12 and 16mmHg. Over the long term this will result in improved bleb function and eventual control of IOP without medication in most cases. A very low dose of acetazolamide (eg. 60mg, twice a day) is often all that is needed to reduce the IOP to a low normal range. Other effective hypotensive agents are topical beta blockers eg timolol, topical or systemic carbonic anhydrase inhibitors eg acetazolamide and topical adrenergic agents eg epinephrine, these may be used singly or in combination.

Surgical steps summarised - Part 1. Surgical technique for translimbal insertion

Step 1. Selecting a quadrant for the Molteno[®] glaucoma implant

Step 2. The incision

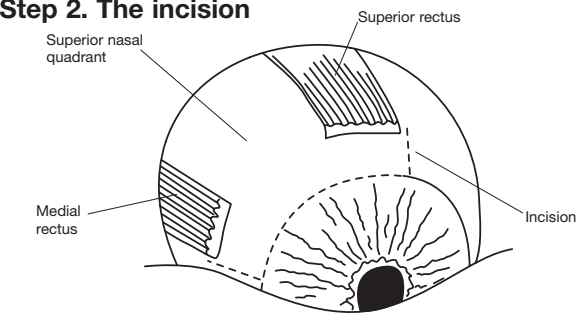


Fig. 2 The incision. (Left eye shown as an example)

Step 3. Fixing the position of the eye and exposing the sclera

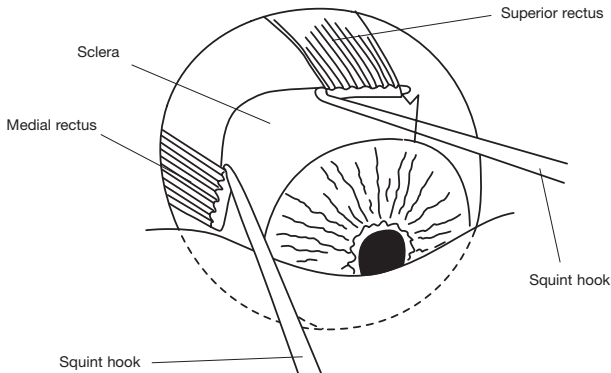


Fig. 3.1 Rotating the eye.

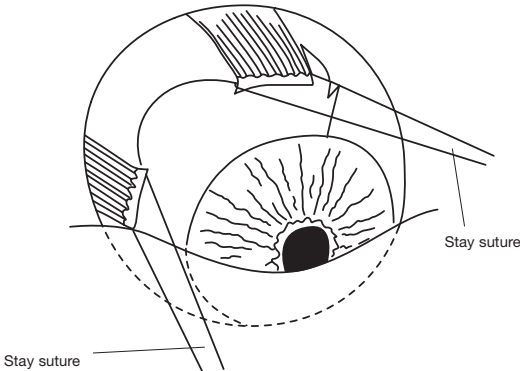


Fig. 3.2 Fixing the position of the eye.

Step 4. Raising a lamellar scleral flap hinged at the limbus

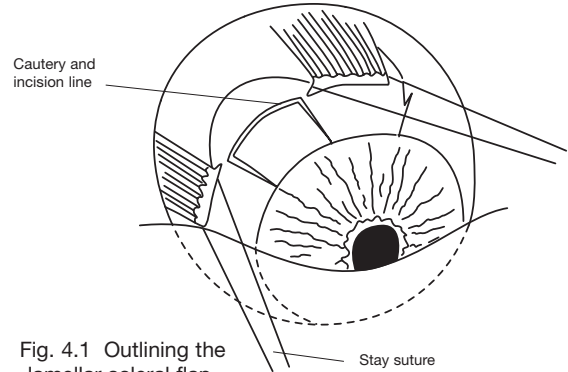


Fig. 4.1 Outlining the lamellar scleral flap.

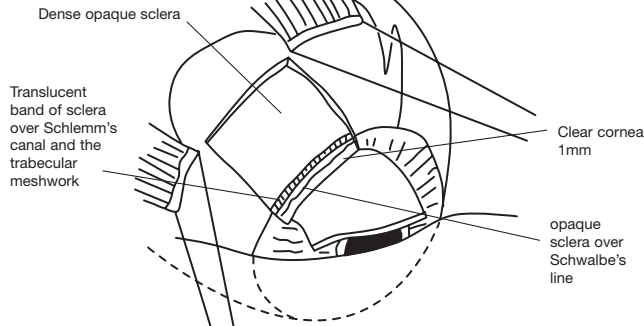


Fig. 4.2 Raising the half thickness flap and dissecting forward for 1mm into clear cornea.

Step 5. Positioning the plate of the implant

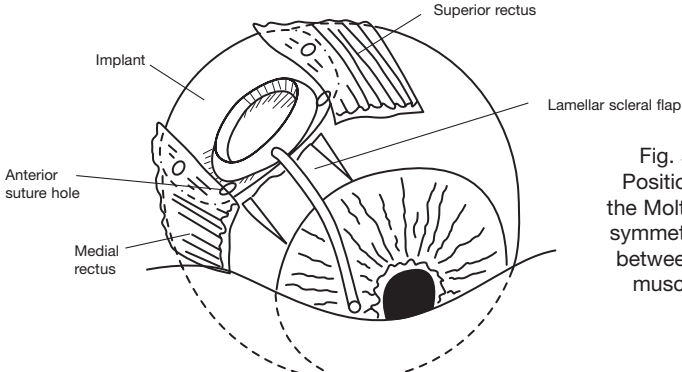
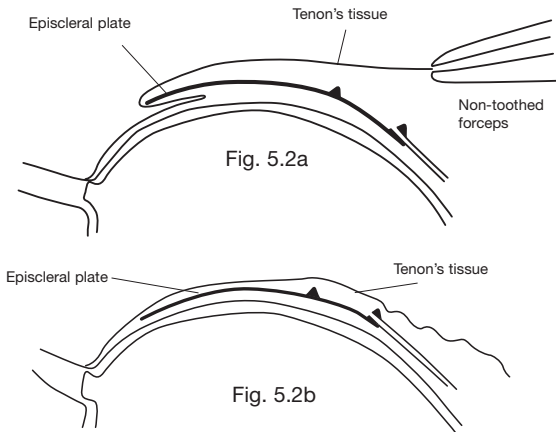


Fig. 5.1 Positioning the Molteno[®] symmetrically between the muscles.

Step 5. cont.

Fig. 5.2 Sectional diagram to show (5.2a) a fold of Tenon's tissue caught behind an episcleral plate and (5.2b) Tenon's tissue freed (see text)



Step 6. Suturing the plate of the implant in position

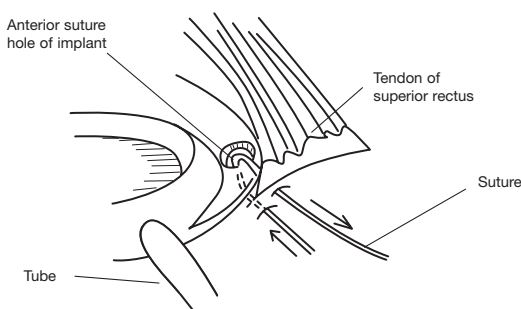


Fig. 6.1 Suturing the episcleral plate of the implant to the sclera with a mattress stitch.

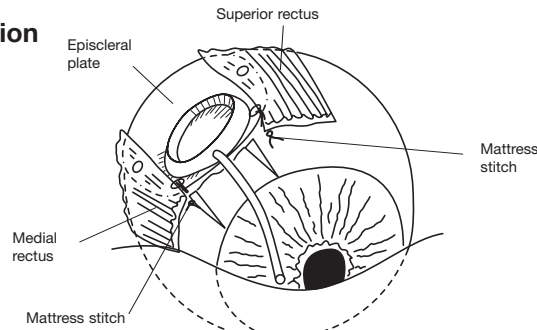


Fig. 6.2 Molteno[®] sutured in position on the sclera with the episcleral plate correctly placed with its anterior edge in the line with the insertions of the rectus muscles.

Step 7. Temporary occlusion of the translimbal tube with an absorbable suture

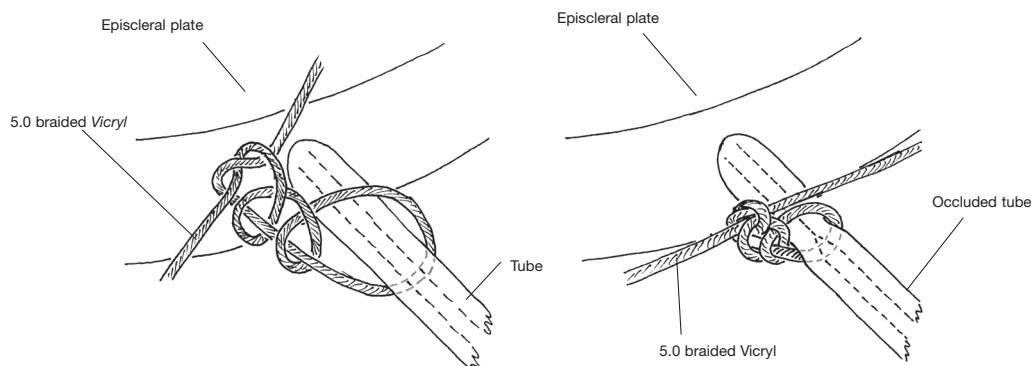


Fig. 7.1 Occluding the tube with an absorbable suture (eg 5.0 braided Vicryl).

**Step 7b (Optional) Temporary valve
Making a relieving slit in the translimbal tube: "Sherwood slit"**

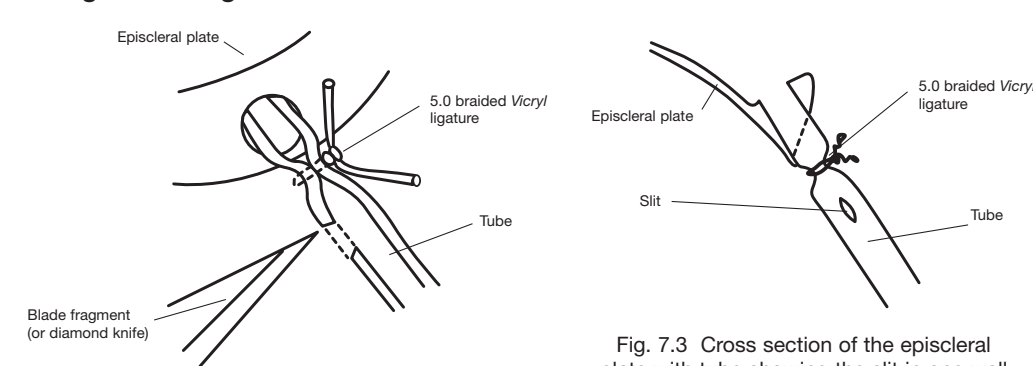


Fig. 7.3 Cross section of the episcleral plate with tube showing the slit in one wall of the tube.

**Step 8. (Optional) - for immediate drainage only
Forming a pressure sensitive 'biological valve' by stretching Tenon's tissue over the subsidiary ridge of the Implant in cases where the Vicryl tie is not used**

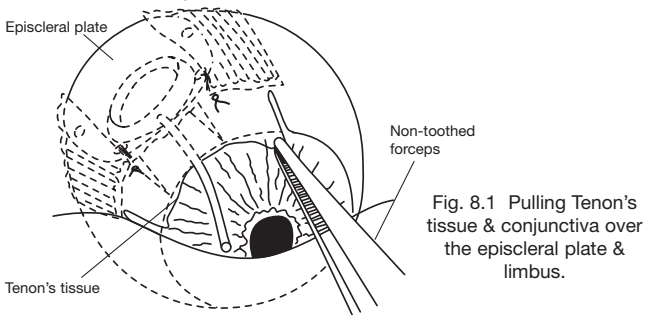


Fig. 8.1 Pulling Tenon's tissue & conjunctiva over the episcleral plate & limbus.

Fig. 8.2 Lifting Tenon's tissue and conjunctiva to expose the undersurface of Tenon's tissue. Suturing Tenon's tissue to sclera in front of the plate.

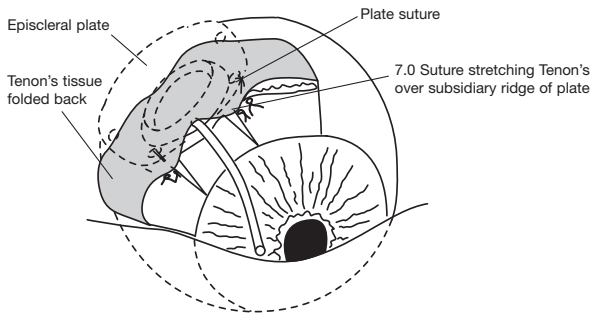
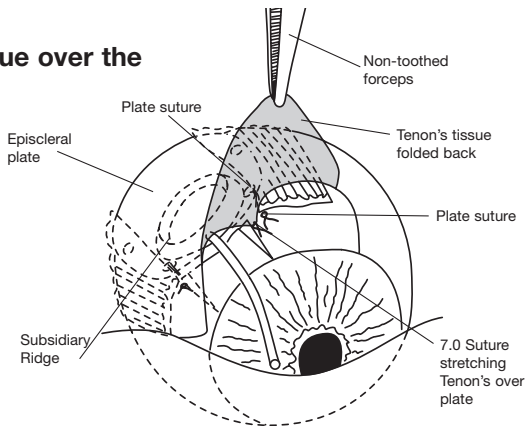


Fig. 8.3 Tenon's tissue sutured to sclera in front of the plate.

Step 9. Trimming the translimbal tube to the correct length

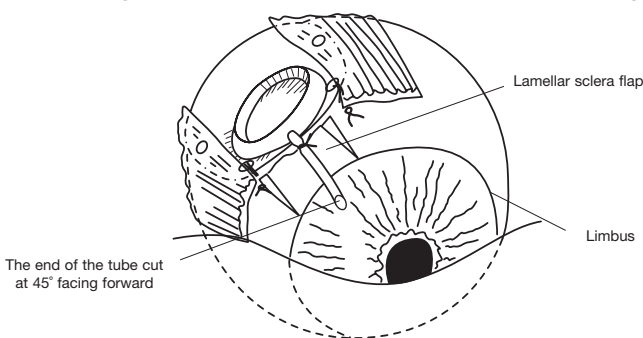


Fig. 9.1 The tube trimmed at 45 degrees so that its point overlaps the limbus by 1.5 - 2mm.

Step 10. Forming a channel for the tube to pass into the AC

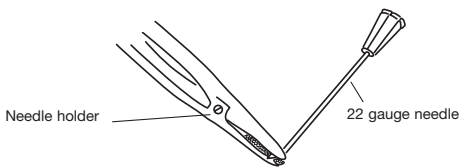


Fig. 10.1 Bending the tip of the 22 gauge needle to an angle of 30° to form a microkeratome.

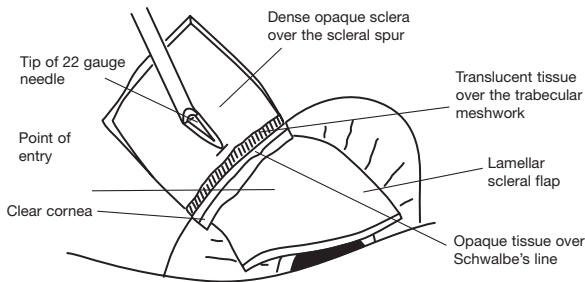


Fig. 10.2 Point of Entry through the bed of the scleral flap.

Step 10. Cont...

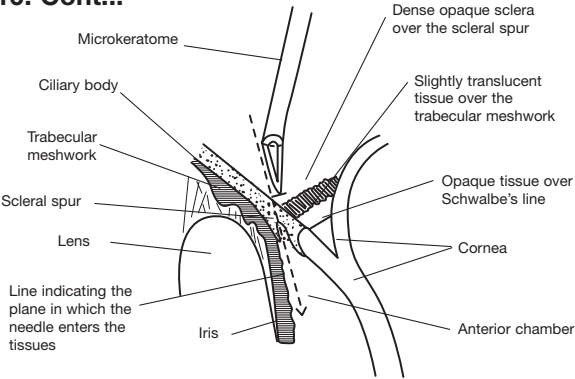


Fig. 10.3 The track of the needle through the tissues into the anterior chamber.

Step 11. Inserting the translimbal tube into the AC

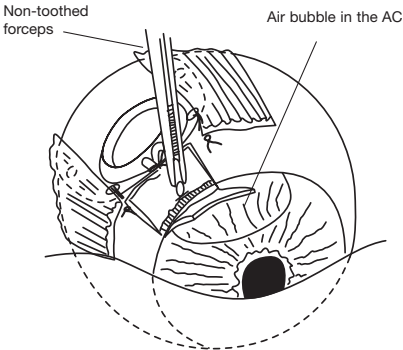


Fig. 11.1 Inserting the tube into the needle track.

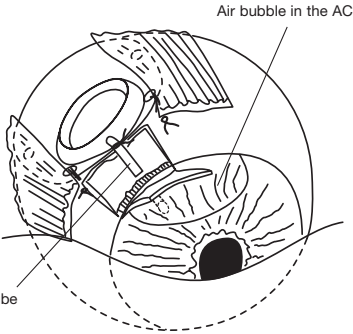


Fig. 11.2 Feeding the tube down the needle track into the AC.

Step 12. Covering the tube of the implant

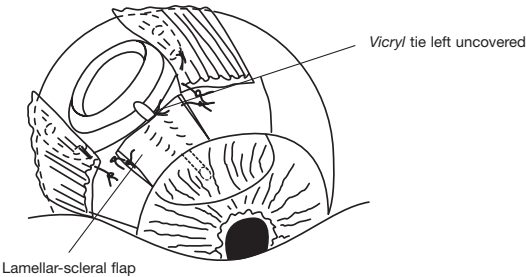


Fig. 12.1 The tube covered by the lamellar-scleral flap having the knot of the Vicryl tie exposed.

Step 12. (Optional) Covering the tube of the implant with donor sclera

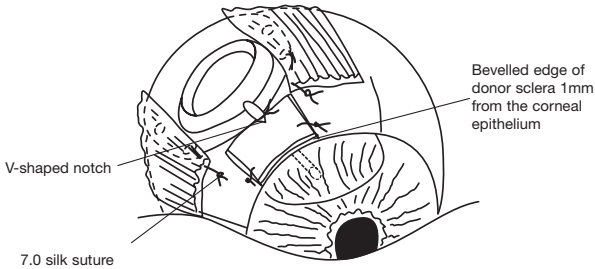


Fig. 12.2 Where donor sclera is indicated: Reinforcing the scleral flap with donor sclera. Note. V-shaped notch to expose the Vicryl tie to vascular tissue.

Step 13. Closure of Tenon's tissue and the conjunctiva

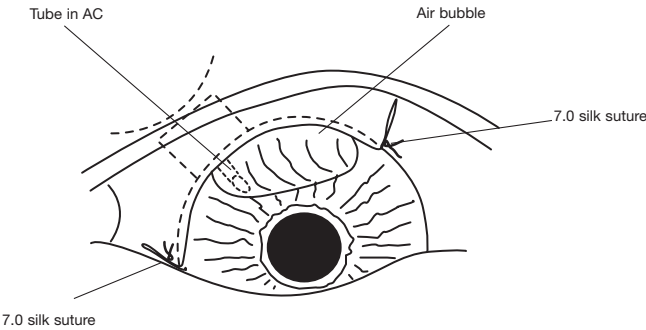
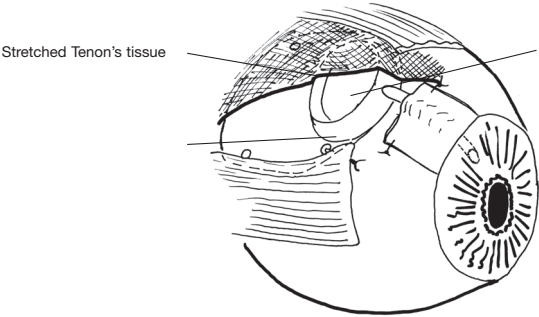
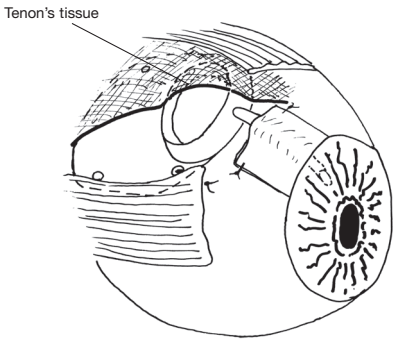


Fig. 13 The conjunctiva sutured over the limbus.

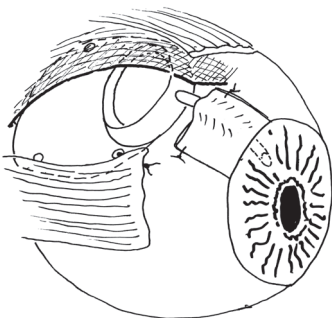
Postoperative action of the temporary pressure sensitive 'biological valve'



Stage 1. One to 14 days after operation. Aqueous drains into the small chamber formed by Tenon's tissue and the subsidiary ridge of the implant prevents the escape of aqueous into the main bleb cavity.



Stage 2. Forteen to 21 days after operation. Tenon's tissue starting to lift off the ridge



Stage 3. Tenon's tissue with its fibrous bleb lining, distended by aqueous and the 'biological valve' no longer active.

Surgical steps summarised - Part 2. Surgical technique for the pars plana insertion of the Molteno3®.

Step 1. Selecting a quadrant for the Molteno3® glaucoma implant

Step 2. The incision

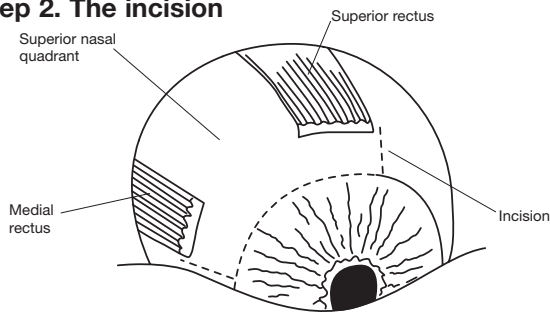


Fig. 2 The incision. (Left eye shown as an example)

Step 3. Fixing the position of the eye and exposing the sclera

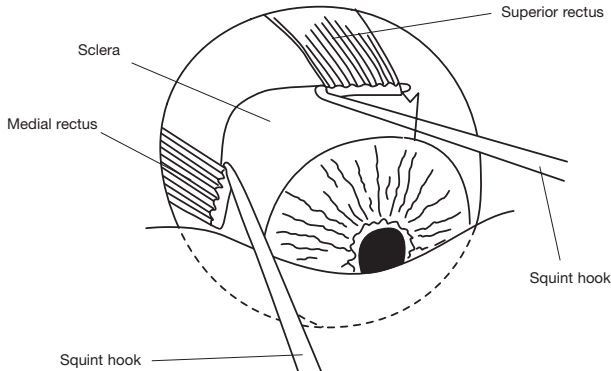


Fig. 3.1 Rotating the eye.

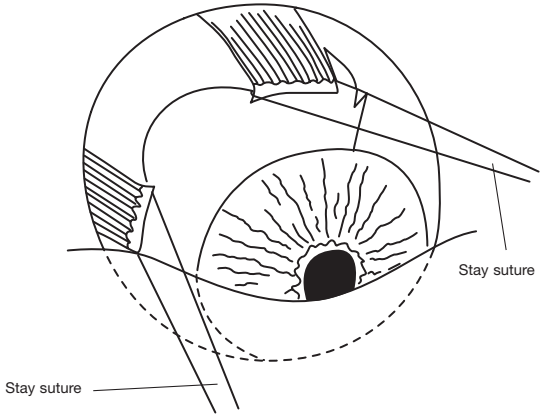


Fig. 3.2 Fixing the position of the eye.

Step 4. The scleral incision

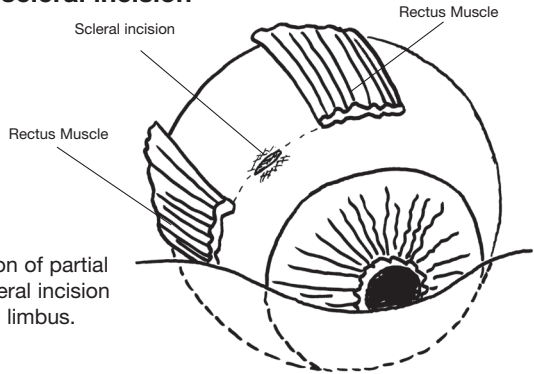


Fig. 4 Position of partial thickness scleral incision parallel to limbus.

Step 5. Positioning the plate of the implant

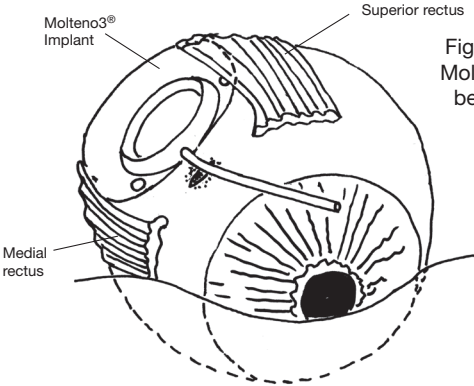


Fig. 5.1 Positioning the Molteno3® symmetrically between the muscles.

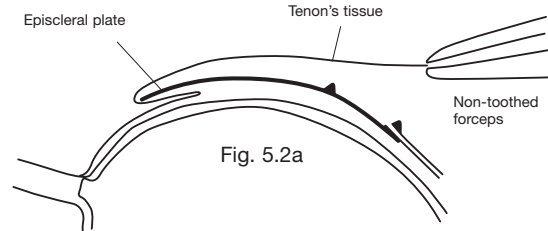


Fig. 5.2a

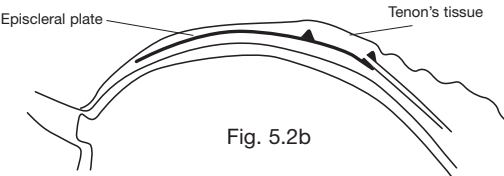
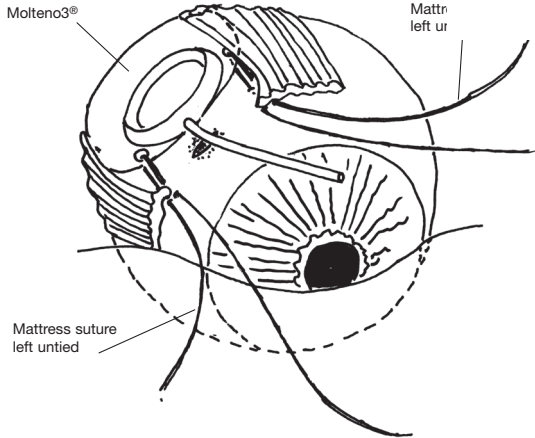


Fig. 5.2b

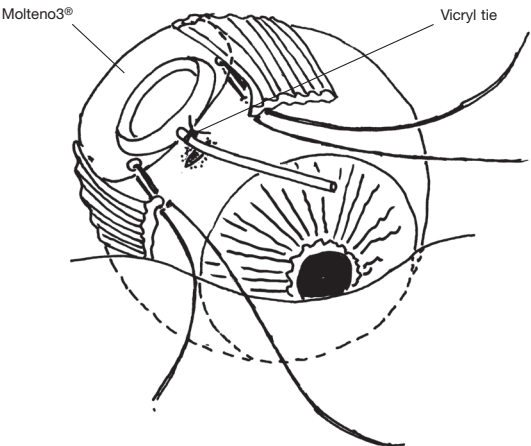
Step 6. Placing sutures to attach the plate of the implant to the sclera

Fig. 6 Molteno3® positioned on the sclera between the rectus muscles with sutures placed but not tied.



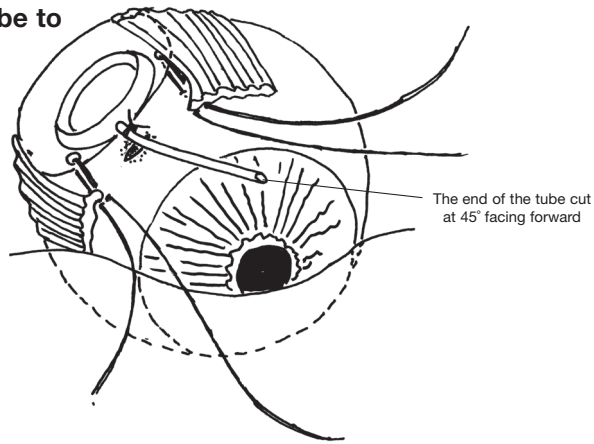
Step 7. Temporary occlusion of the translimbal tube with an absorbable suture "Vicryl tie"

Fig. 7 Occluding the tube with an absorbable suture (eg 5.0 braided Vicryl) close to the plate of the implant.



Step 8. Trimming the tube to the correct length

Fig. 8 The tube trimmed at 45 degrees so that its point facing forward 5-8mm from the plate.



Step 9. Forming a channel for the tube to pass into the posterior chamber

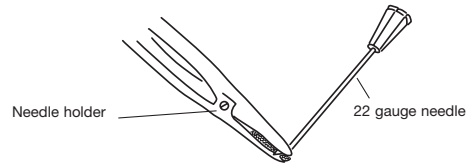


Fig. 9.1 Bending the tip of the 22 gauge needle to an angle of 30° to form a microkeratome.

22 Gauge with bent tip forming a Microkeratome

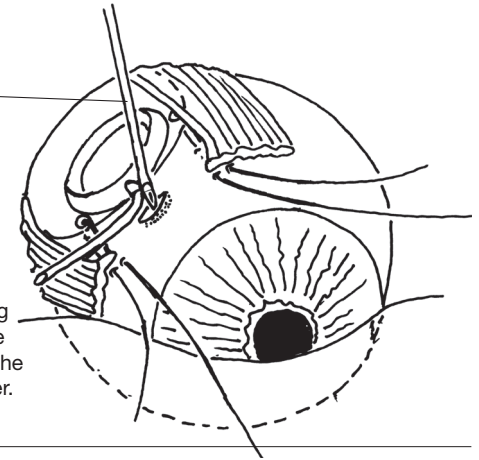


Fig. 9.2 Forming a channel for the tube to pass into the posterior chamber.

Step 10. Inserting the tube into the posterior chamber

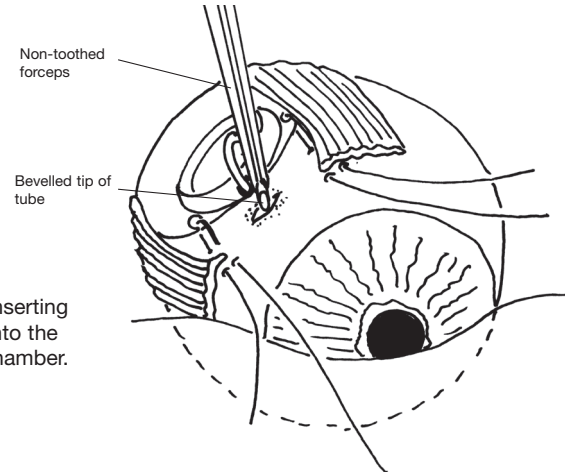


Fig. 10.1 Inserting the tube into the posterior chamber.

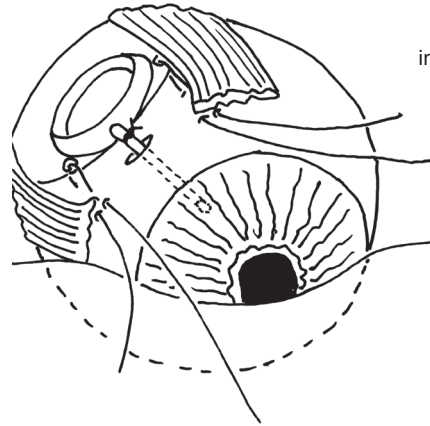


Fig. 10.2 Tube inserted into posterior chamber.

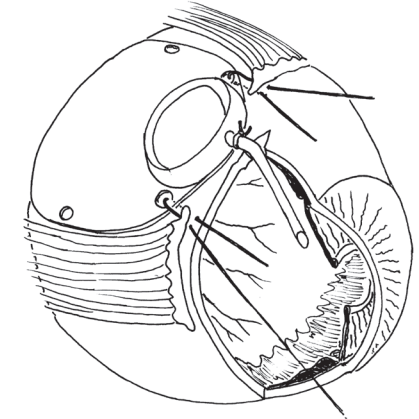


Fig. 10.3 Position of tube in posterior chamber before tying sutures.

Step 11. Tying the preplaced mattress sutures to adjust the angle of the tube in the posterior chamber and to fix the plate in position on the sclera

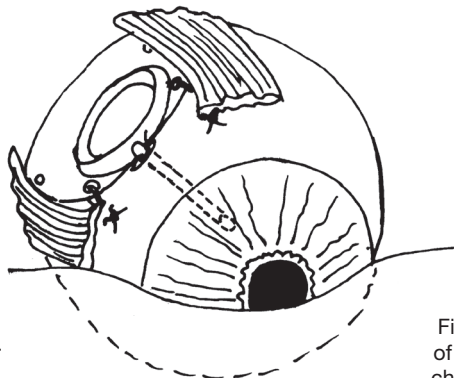


Fig. 11.1 Tube in posterior chamber after tying sutures.

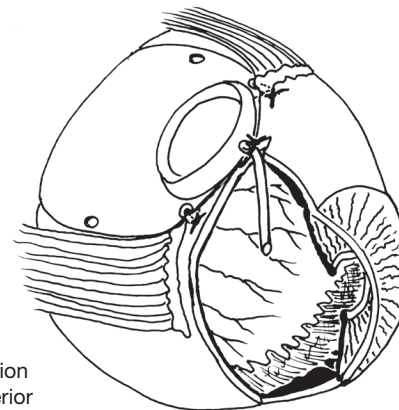


Fig. 11.2 Position of tube in posterior chamber after tying sutures.

Step 12. Closure of Tenon's tissue and conjunctiva

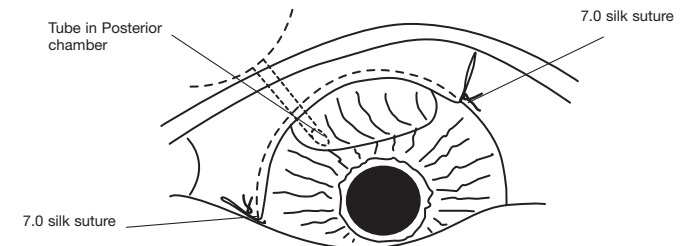


Fig. 12 The conjunctiva sutured over the limbus.

Notes

Notes