

ARTICLE

Implantation of a diffractive–refractive trifocal intraocular lens with centralized diffractive rings: Two-year results



Jozsef F. Gyory, MD, Edina Madár, MD, Sathish Srinivasan, FRCSEd, FRCOphth, FACS

Purpose: To compare the optical performance and quality of life after implantation of a new progressively apodized diffractive multifocal intraocular lens (IOL) and report the visual and patient-reported outcomes and contrast sensitivity.

Setting: Csolnoky Ferenc Hospital, Veszprem, Hungary.

Design: Prospective case series.

Methods: Patients had bilateral implantation of the trifocal IOL during cataract surgery. The preoperative corrected distance visual acuity (CDVA) and postoperative uncorrected distance visual acuity (UDVA), CDVA, uncorrected (UIVA) and corrected (CIVA) intermediate visual acuities, and uncorrected (UNVA) and corrected (CNVA) near visual acuities (all logarithm of the minimum angle of resolution) were collected. Contrast sensitivity, slitlamp photographs for evaluation of posterior capsule opacification, and a quality-of-vision questionnaire were assessed.

Results: The study comprised 100 eyes (50 patients). The mean postoperative UDVA was 0.01 at 3, 6, 12, and 24 months. The mean CDVA was -0.02 ± 0.03 (SD) at 6 months, -0.04 ± 0.05 at 1 year, and 0.06 ± 0.05 at 2 years. The mean UIVA was 0.05 ± 0.11 , 0.04 ± 0.09 , and 0.06 ± 0.11 , respectively. The mean CIVA was -0.01 ± 0.07 , -0.02 ± 0.06 , and -0.01 ± 0.07 , respectively. The mean UNVA was 0.08 ± 0.08 , 0.07 ± 0.08 , and 0.10 ± 0.09 , respectively. The mean CNVA was 0.03 ± 0.06 at 3 months, 0.04 ± 0.05 at 1 year, and 0.05 ± 0.07 at 2 years. The mesopic and photopic contrast sensitivity values were within the upper normal range for age-matched values.

Conclusions: Bilateral implantation of a new trifocal IOL with centralized diffractive rings provided good functional vision at all distances. The levels of spectacle independence and patient satisfaction were high with minimal dysphotopsia symptoms.

J Cataract Refract Surg 2019; 45:639–646 Crown Copyright © 2019 Published by Elsevier Inc. on behalf of ASCRS and ESCRS. All rights reserved.

Cataract surgery is the most commonly performed surgical procedure worldwide, with more than 4.2 million cataract procedures performed across the European Union member states per annum.¹ Modern-day cataract surgery has evolved into refractive cataract surgery in which the surgeon can customize and tailor the refractive outcomes for each individual patient. With modern lifestyles, patients expect and demand a good functional range of unaided vision after cataract surgery. Multifocal intraocular lens (IOL) implantation during cataract surgery has become an important tool in rehabilitating and meeting the visual needs of patients. Since the introduction of the first multifocal IOL in the 1990s, technological advancements have led to a plethora of IOL choices.

At present, the choices of presbyopia-correcting IOLs include diffractive bifocal, segmental bifocal, trifocal, and extended depth of focus. A recent Cochrane review² reported that multifocal IOLs are effective in improving the near vision and patients receiving multifocal IOLs are less likely to be spectacle dependent than patients receiving monovision IOLs. Most first-generation multifocal IOLs incorporated a 4.0 diopter (D) reading addition (add) at the lenticular plane to minimize the risk for diplopia and image confusion resulting from the superimposition of simultaneous sharp images and defocused images while still enabling useful near vision. Defocus curves of the multifocal IOLs show 2 visual peaks at distance and near, with patients missing out on intermediate vision between 60 cm and 80 cm. Subsequent generations of multifocal

Submitted: November 13, 2018 | Final revision submitted: January 16, 2019 | Accepted: January 17, 2019

From the Department of Ophthalmology (Gyory, Madár), Csolnoky Ferenc Hospital, Veszprem, Hungary; Department of Ophthalmology (Srinivasan), University Hospital Ayr, and University of West of Scotland (Srinivasan), Ayr, United Kingdom.

Presented in part at the XXXV Congress of the European Society of Cataract and Refractive Surgeons, Lisbon, Portugal, October 2017.

Corresponding author: Sathish Srinivasan, FRCSEd, FRCOphth, FACS, Department of Ophthalmology, 3rd Floor, University Hospital Ayr, Dalmellington Rd, Ayr, KA6 DX, United Kingdom. Email: sathish.srinivasan@gmail.com.

Crown Copyright © 2019 Published by Elsevier Inc. on behalf of ASCRS and ESCRS. All rights reserved.

0886-3350/\$ - see frontmatter
<https://doi.org/10.1016/j.jcrs.2019.01.024>

IOLs have reduced the near add, which ranges from 3.00 to 2.50 D, in an attempt to improve intermediate vision.^{3,4}

More recently, IOLs with trifocal optics were introduced to enhance intermediate vision. Further optical modifications, including variations in asphericity and diffractive step profile variations, have been developed to improve the quality of vision.^{5–7} The third foci generated by these IOLs are obtained by combining 2 bifocal diffractive profiles on 1 surface of the IOL⁸ or by using a trifocal diffractive profile combined with a bifocal diffractive optic.⁷ Trifocal diffractive IOL reportedly “smooth out” the defocus curve and provide a good range of vision from 0.00 to –3.00 D.^{9,10} We report the visual and refractive outcomes and contrast sensitivity in eyes that had bilateral implantation of a new hydrophilic progressively apodized diffractive–refractive trifocal IOL during cataract surgery.

PATIENTS AND METHODS

In this prospective single-center trial, patients had cataract surgery with bilateral implantation of an apodized diffractive–refractive trifocal IOL performed by the same surgeon (J.F.G.). All patients provided informed consent preoperatively after receiving a detailed explanation of the surgery, possible benefits, and risks. The study was performed in accordance with the tenets of the Declaration of Helsinki and was approved by the Health Science and Research Ethical Board Committee of Hungary (OGYEL, Hungarian Health Authority, reference: 032802/2014/OTIG).

The inclusion criteria were age more than 35 years, bilateral cataract, and preexisting corneal astigmatism less than 1.25 D. The exclusion criteria were coexisting ocular morbidities including preexisting corneal scars, macular pathology, and amblyopia.

Preoperative Assessment

All patients had a complete ocular examination including uncorrected (UDVA) and corrected (CDVA) distance visual acuities and near acuity measurements with Early Treatment Diabetic Retinopathy Study and Radner charts, respectively; applanation tonometry; and dilated posterior segment evaluation. All patients had noncontact biometry (IOLMaster, Carl Zeiss Meditec AG) and optical coherence tomography (Spectralis, Heidelberg Engineering GmbH) of the macula. A proprietary online calculator from the manufacturer was used for IOL power calculations.^A The IOL power was calculated to achieve emmetropia in all cases.

Intraocular Lens

The Liberty Bi-Flex 677MY (Medicontur Medical Engineering Ltd., Inc.) is a trifocal single-piece aspheric. It is made of hydrophilic acrylic with an ultraviolet filter and a yellow filter. The IOL has very low chromatic aberration (Abbe number 58). The optic diameter is 6.0 mm, and the overall length is 13.0 mm. It has a 360-degree square edge, which includes the haptic–optic junction. The IOL has a closed double C-loop haptic design with planar angulation (Figure 1). The haptics have an 88.8-degree contact angle, with the equatorial part of the capsular bag designed to provide enhanced stability and centration in the capsular bag. The anterior surface of the optic has a progressively apodized diffractive zone. Unlike the other trifocal IOLs, this IOL has only 7 concentric diffractive steps that are located in the central 3.0 mm zone of the optic. These apodized diffractive rings are arranged in a configuration that causes an elevated phase shift of the interference patterns, providing distance and near foci; the constructive interference of the far and near foci produces an intermediate peak for intermediate vision (Figure 2). The IOL power

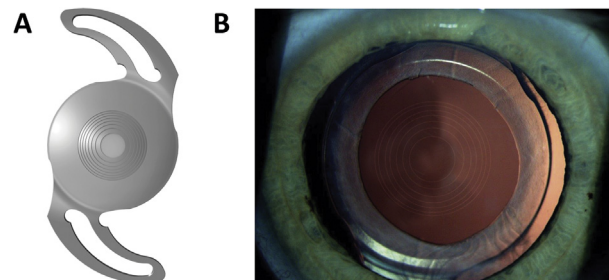


Figure 1. A: Trifocal IOL with central 7 diffractive rings. B: Clinical photograph of the trifocal IOL in the capsular bag (IOL = intraocular lens).

ranges from 0.0 to 30.0 D in 0.5 D increments and from 31.0 to 35.0 D in 1.0 D increments. It has an intermediate add of 1.75 D and near-vision add of 3.5 D at the IOL plane, which translate to 1.35 D and 2.70 D at the spectacle plane, respectively. The IOL is injected through a 2.2 mm clear corneal incision with a custom injector.

Surgical Technique

Surgery was performed using a standard technique of sutureless phacoemulsification through a temporal 2.65 mm clear corneal incision under topical anesthesia of oxybuprocaine hydrochloride 0.4% (Humacain). In cases in which the preexisting corneal astigmatism exceeded 0.75 D, the clear corneal incision was placed in the steep meridian. After cataract extraction, the trifocal IOL was loaded into a custom cartridge and injected into the capsular bag. Postoperatively, all patients received topical moxifloxacin (Vigamox), nepafenac (Nevanac), and dexamethasone (Maxidex) for 4 weeks.

Postoperative Assessment

Postoperatively, all patients were evaluated at 1 day, 1 week, and 1, 3, 6, 12, and 24 months. At each visit, the UDVA and CDVA at 6 m, uncorrected (UIVA) and corrected intermediate (CIVA) visual acuities at 60 cm, and uncorrected (UNVA) and corrected (CNVA) near visual acuities at 40 cm were measured. During each visit, digital slitlamp photographs were obtained with the pupil dilated to determine whether posterior capsule opacification was present. Postoperatively, all patients filled in a quality-of-life questionnaire^B (National Eye Institute Visual Functioning Questionnaire–25 [VFQ-25]) at 3, 6, 12, and 24 months.

Contrast Sensitivity

Contrast sensitivity was measured with a standardized contrast sensitivity chart (CSV 1000, Vision Sciences Research Corp.). The chart provides a fluorescent luminance source that retroilluminates a translucent chart. The instrument houses a series of photocells that automatically monitor and calibrate the instrument light level to 85 candelas/m² ± log unit. The testing light levels were all within ±0.1 log unit at each spatial frequency. At a testing distance of 8 feet, the translucent chart presents the following 4 spatial frequencies: 3, 6, 12, and 18 cycles per degree (cpd). Each spatial frequency is presented on a separate test row. Each row represents 17 circular patches that are 1.5 inches in diameter. The first patch in each row is a test sample patch that represents a very-high-contrast grating. The remaining 16 patches appear in 8 columns presented across the row. In each column, one patch represents grating and the other patch is blank. The patches with gratings decrease in contrast moving from left to right across the row. The patient is directed to observe the first sample patch and to look for grating patterns in each column. The contrast level of the last correct response is recorded as the contrast threshold. The other option to test contrast threshold

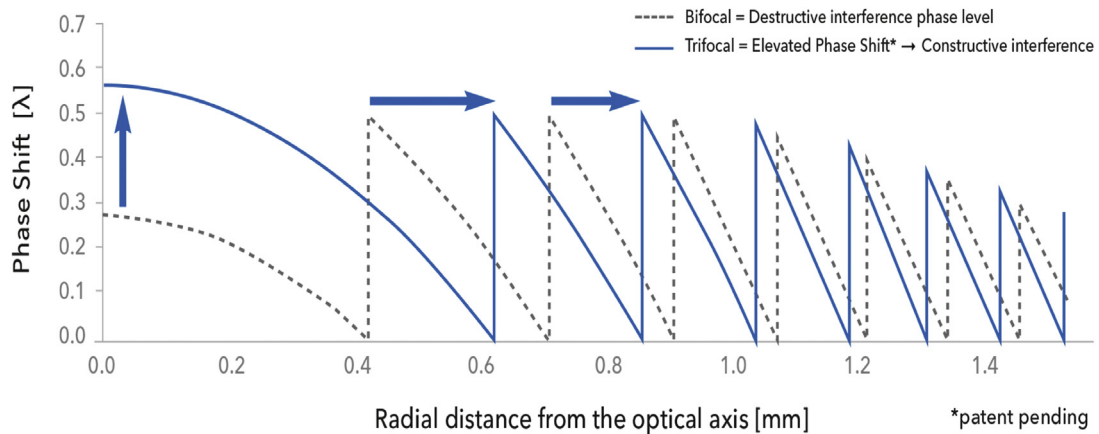


Figure 2. Schematic diagram of the elevated phase shift technology. (*Patent pending by Medicontur Ltd.)

would be the online computer-based Frankfurt Freiburg contrast and acuity test system. This system was not used because in the authors' experience, the CSV 1000 is a more robust and standardized way of measuring contrast sensitivity and the authors have more experience using this system. Contrast sensitivity was measured postoperatively at 3, 6, 12, and 24 months.

Statistical Analysis

For contrast sensitivity, descriptive statistics for each spatial frequency and postoperative follow-up visit were performed. Normality of data was evaluated using the Shapiro-Wilk test. The nonparametric Kruskal-Wallis test with Dunn multiple comparisons was performed to analyze the mean rank differences between the follow-up visits at each spatial frequency. A *P* value less than 0.05 was considered significant. Statistical analysis was performed using Prism 7 software (GraphPad Software).

Monocular and binocular defocus curve measurements were performed at 6-, 12-, and 24-month visits. Data collected were entered in an Excel spreadsheet (version 14.0.7181.5000, Microsoft Corp.). Statistical analysis was performed with SPSS for Windows software (version 21.0, IBM Corp.). The mean values and standard deviations were calculated for every parameter. The Wilcoxon rank-sum test, a nonparametric statistical test, was applied to assess the significance of differences in parameters between postoperative follow-ups (*P* < .05).

RESULTS

The study comprised 100 eyes (50 patients). The mean age of the cohort was 60.74 years (range 36 to 81 years). No patient was lost to follow-up at 1 year; however, 9 eyes were lost to follow-up at 2 years. There were no intraoperative or postoperative complications during the 1-year follow-up.

Visual Acuity and Refraction

The mean postoperative UDVA was 0.01 logarithm of the minimum angle of resolution (logMAR) at 3, 6, 12, and 24 months. The mean CDVA was -0.02 ± 0.03 logMAR at 3 and 6 months, -0.04 ± 0.05 logMAR at 1 year, and 0.06 ± 0.05 logMAR at 2 years. The mean UIVA was 0.05 ± 0.11 logMAR, 0.04 ± 0.09 logMAR, and 0.06 ± 0.11 logMAR, respectively. The mean CIVA was -0.01 ± 0.07 logMAR, -0.02 ± 0.06 logMAR, and -0.01 ± 0.07 logMAR, respectively. The mean UNVA was 0.08 ± 0.08 logMAR, 0.07 ± 0.08 logMAR, and 0.10 ± 0.09 logMAR, respectively. The mean CNVA was

0.03 ± 0.06 logMAR at 3 months, 0.04 ± 0.05 logMAR at 1 year, and 0.05 ± 0.07 logMAR at 2 years.

Figure 3 shows the cumulative postoperative UDVA compared with the postoperative CDVA at 3, 6, 12, and 24 months. Figure 4 shows the cumulative postoperative UIVA compared with the postoperative CIVA over time. Figure 5 shows the postoperative UNVA compared with the postoperative CNVA over time. Fifty-four eyes (54%) had the same UDVA as the CDVA, and 91 eyes (91%) were within 1 line of the CDVA (Figure 6).

Ninety-four eyes (94%) were within ± 0.50 D of the expected postoperative mean spherical equivalent (Figure 7). Postoperatively, the refractive cylinder was less than 0.50 D in 96 eyes (96%) (Figure 8).

Defocus Curves

Figure 9 shows the mean logMAR visual acuities for different defocus values 12 months and 24 months postoperatively. The results show that the trifocal IOL provided good levels of functional vision from +0.50 D to -3.00 D at the 2-year follow-up.

Contrast Sensitivity

Figure 10 shows the mean postoperative contrast sensitivity at 3, 6, 12, and 24 months. The contrast sensitivity values were in the upper third range of age-matched normal values. The mean values at low, medium, and higher spatial frequencies remained unchanged until 1 year postoperatively. At 2 years, however, the mean values were significantly reduced at low spatial frequencies (3 cpd and 6 cpd) under mesopic conditions (*P* = .009 and *P* < .038, respectively). Under scotopic conditions at 2 years, all spatial frequencies except 3 cpd showed a significant reduction (6 cpd: *P* = .0098; 12 cpd: *P* = .0018; 18 cpd: *P* = .0126).

Patient-Reported Outcome Measures

After surgery, all patients in the cohort completed the VFQ-25 at 3, 6, 12, and 24 months. The cumulative results are summarized in Table 1. Twenty-eight patients (56%) reported no to mild halos, while 18 patients (36%) reported no to mild difficulty with nighttime driving.

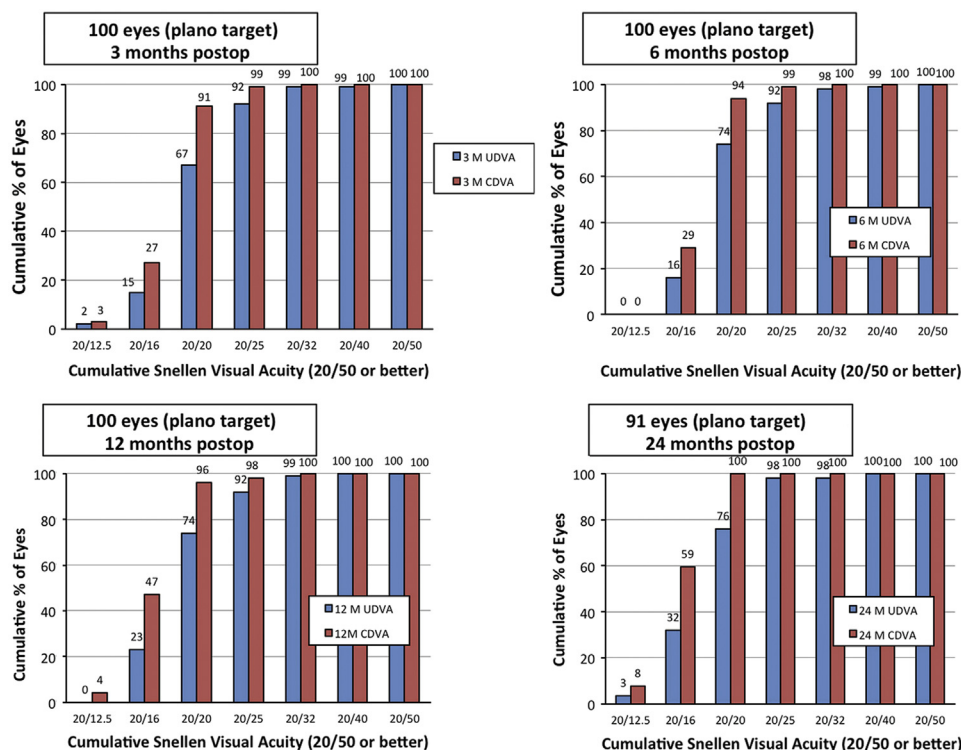


Figure 3. Cumulative postoperative UDVA compared with postoperative CDVA over time (CDVA = corrected distance visual acuity; UDVA = uncorrected distance visual acuity).

DISCUSSION

The loss of near vision in presbyopic patients negatively affects the quality of life.^{11,12} In a population study based in the United States, McDonnell et al.¹² found that presbyopia was associated with substantial negative effects on health-related quality of life. At present, the surgical strategies for treating presbyopia can be broadly

classified as techniques that work at the corneal plane and those that work at the lenticular plane. However, the lenticular option seems to be preferred for correcting presbyopia in older presbyopic patients and in patients with cataracts.

Traditionally, surgeons implanted a monofocal IOL during cataract surgery, which provided optical

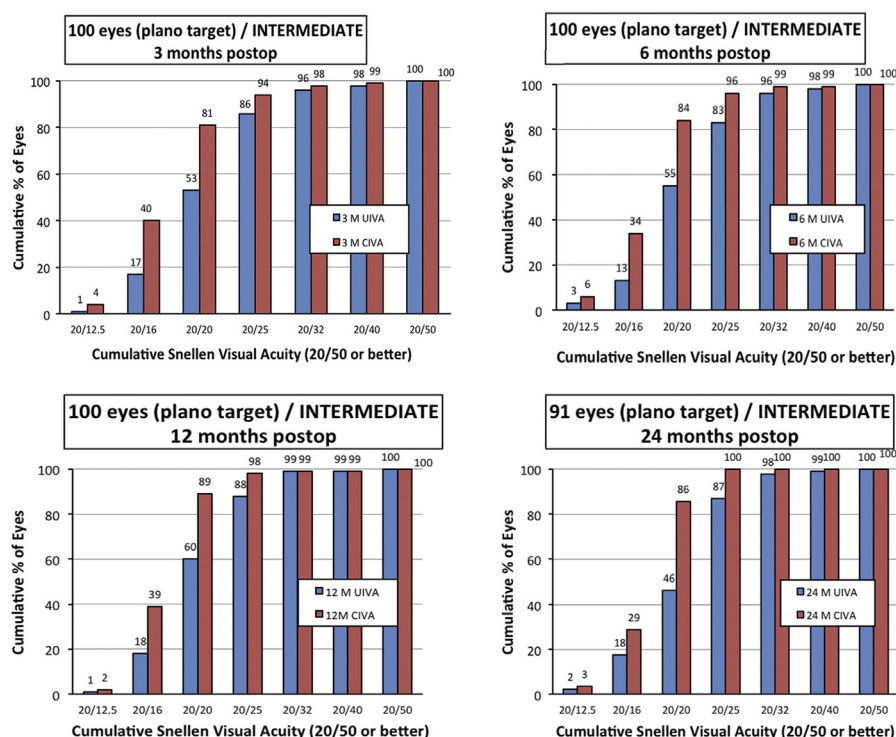


Figure 4. Cumulative postoperative UIVA compared with postoperative CIVA over time (CIVA = corrected intermediate visual acuity; UIVA = uncorrected intermediate visual acuity).

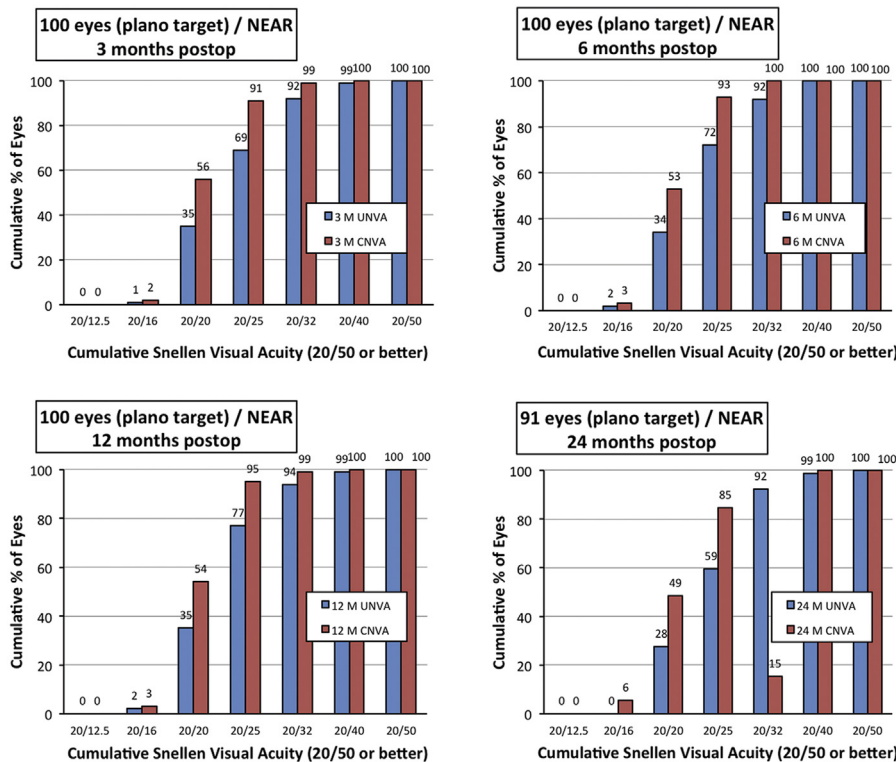


Figure 5. Cumulative postoperative UNVA compared with postoperative CNVA over time (CNVA = corrected near visual acuity; UNVA = uncorrected near visual acuity).

correction at distance only. Thus, patients required spectacle correction for intermediate vision and near vision postoperatively. Monovision with monofocal IOLs was tried as an option to decrease the dependency of spectacle wear for near vision. However, the optics and design of presbyopia-correcting IOLs have advanced in the past 3 decades. The first U.S. Food and Drug Administration–approved multifocal IOL was the Array (Advanced Medical Optics, Inc.) in 1997.¹³ The optics of multifocal IOLs are designed to provide functional vision at distance and near by creating 2 retinal images corresponding to focused light rays from distance objects and near objects. This creates what has been termed

simultaneous vision.¹⁴ Designs based on diffractive optics have produced better near vision and greater spectacle independence than refractive multifocal IOLs with similar levels of visual symptoms.^{5,15} However, the lack of intermediate vision with traditional multifocal IOLs¹⁶ has led manufacturers to develop trifocal IOLs to provide better quality of vision at distance, intermediate, and near. At present, outside the U.S., several trifocal IOLs are available from different manufacturers (AT LISA tri 839MP, Carl Zeiss Meditec AG; FineVision Micro F, PhysIOL, Inc.; PanOptix, Alcon Laboratories, Inc.). Previous studies^{17–22} have shown that trifocal IOLs provide good functional vision at all distances (including intermediate) with high levels of spectacle independence and patient satisfaction.

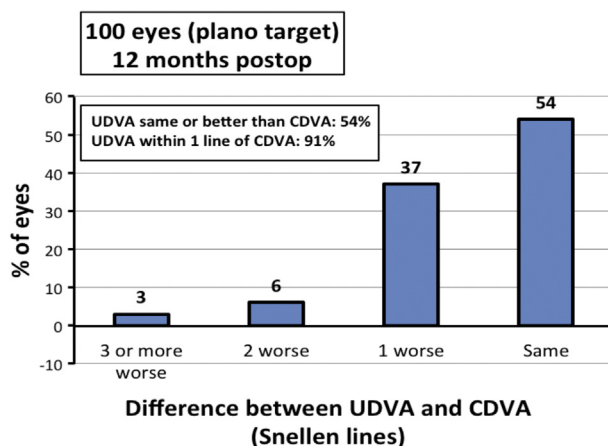


Figure 6. Difference between the postoperative UDVA and preoperative CDVA (CDVA = corrected distance visual acuity; UDVA = uncorrected distance visual acuity).

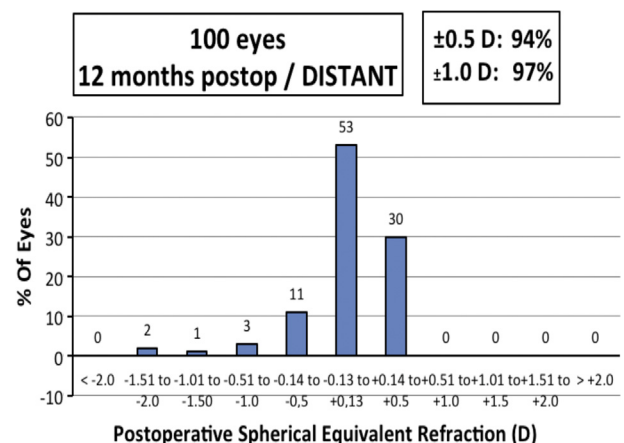


Figure 7. Spread of postoperative mean spherical equivalent.

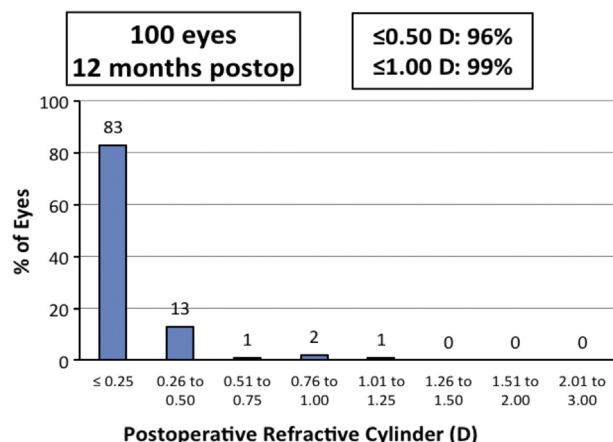


Figure 8. Postoperative refractive cylinder.

In this prospective study, 50 patients who had bilateral implantation of the Liberty Bi-Flex 677MY trifocal IOL were followed for 2 years. The optical principle and structural arrangement of the diffractive rings of the trifocal IOL used in this study differ from those of other commercially available trifocal IOLs. The IOL uses an elevated phase slit technology that causes constructive interference in the wavefront, providing an intermediate peak for intermediate vision. With other trifocal IOLs, the third foci are generated by combining 2 bifocal diffractive profiles on a single surface⁸ or by using a trifocal diffractive profile combined with a bifocal diffractive optic.⁹ Moreover, the Liberty Bi-Flex 677MY trifocal IOL has 7 diffractive rings that are progressively apodized and located in the central 3.00 mm of the 6.00 mm optic, with the rest of the optic being a refractive surface. In comparison, the trifocal AT LISA 839MP IOL has 21 to 29 diffractive rings in the central 4.34 mm zone of the 6.00 optic. The FineVision trifocal IOL has 26 diffractive rings across the entire 6.15 mm optic. The PanOptix trifocal IOL has 15 diffractive rings across the central 4.50 mm of the optic.

In our cohort, the mean postoperative binocular UDVA was 0.01 logMAR at 3, 6, 12, and 24 months. The mean UIVA was 0.05 logMAR at 6 months, 0.04 logMAR at 1 year, and 0.06 logMAR at 2 years. The mean UNVA was 0.08 logMAR, 0.07 logMAR, and 0.10 logMAR, respectively. We presented the visual outcome results according to the recommendations of a joint editorial by the editors of the *Journal of Cataract & Refractive Surgery* and the *Journal of Refractive Surgery*.²³ The postoperative UDVA was the same as or better than the postoperative CDVA in 54% of cases and within 1 line in 91%.

Our visual outcomes compare favorably with other published data on trifocal IOLs.^{7,22} Mojzis et al.⁷ reported first on the clinical results of the AT LISA tri 839MP trifocal diffractive IOL. In their prospective study of 60 eyes followed for 6 months, the mean postoperative UDVA, UIVA, and UNVA were -0.03 ± 0.09 logMAR, 0.08 ± 0.10 logMAR, 0.20 ± 0.12 logMAR, respectively. In a prospective randomized study comparing the results of bilateral implantation of the FineVision IOL or the bifocal AcrySof ReSTOR +3.00 IOL (Alcon Laboratories, Inc.), Jonker et al.²² reported visual acuities of 0.01 ± 0.11 logMAR, 0.32 ± 0.15 logMAR, and 0.15 ± 0.13 logMAR for UDVA, UIVA, UNVA, respectively, in the trifocal group. With regard to the defocus curve analysis, the Liberty Bi-Flex 677MY trifocal IOL provided better visual acuity in the defocus range of +0.50 to -3.00 D compared with the published data for the AT LISA tri 839MP trifocal IOL and the PanOptix IOL.^{24,25} Our results are in accordance with those in a study by Fernández et al.²⁶ that evaluated the same type of trifocal IOL.

A critical issue with the use of a diffractive optics IOL is the quality of vision with regard to contrast sensitivity and postoperative glare, halos, and dysphotopsia symptoms. In the current study, we evaluated photopic and mesopic contrast sensitivity prospectively at 3, 6, 12, and 24 months. Our results are very similar to those reported for different bifocal and trifocal IOLs.²⁷ However, at the 2-year follow-up, there was a significant reduction

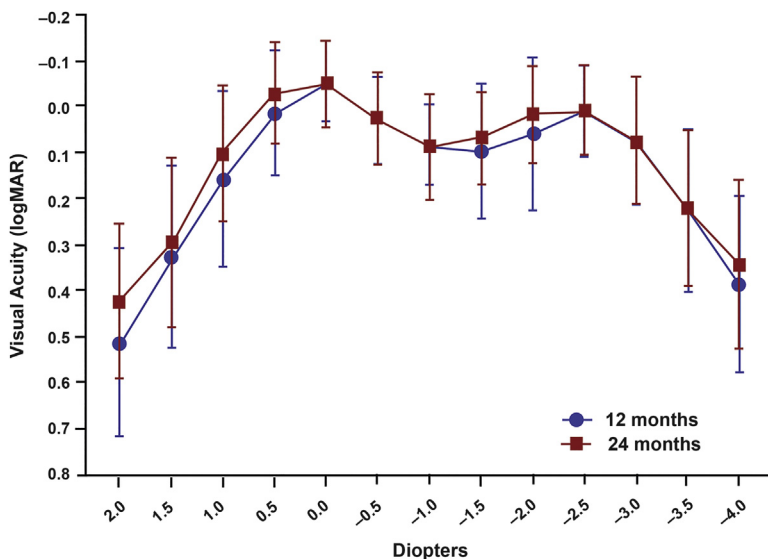


Figure 9. Binocular defocus curve (means \pm SD) (logMAR = logarithm of the minimum angle of resolution).

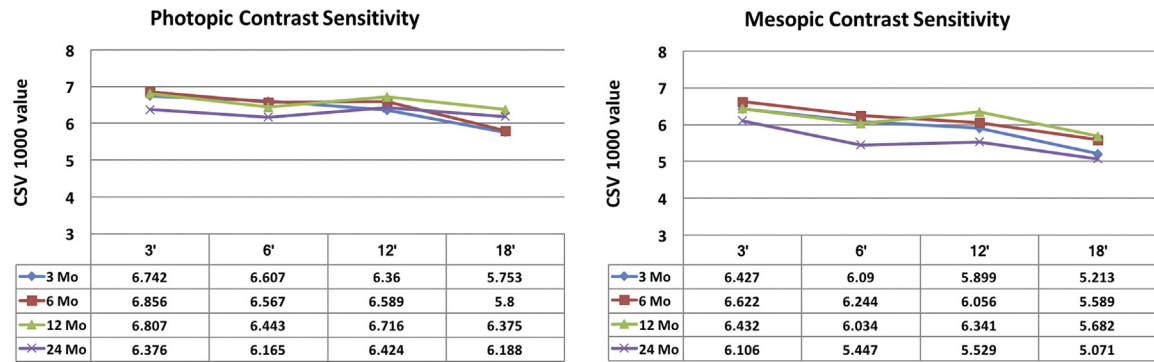


Figure 10. Photopic and mesopic contrast sensitivity (CSV 1000 = contrast sensitivity chart used in study).

in contrast sensitivity at low spatial frequencies (3 cpd and 6 cpd) ($P = .009$ and $P < .038$, respectively) compared with 1-year results. The difference might be attributed to early subclinical posterior capsule opacification. All patients in the cohort completed the VFQ-25 visual functioning questionnaire, on which 96% of patients reported no to mild halos and 96% reported no to mild difficulty with night driving. This high level of patient satisfaction with minimal postoperative visual

symptoms might be attributable to the minimal diffractive steps limited to the central 3.00 of the optic of the trifocal IOL.

In conclusion, this new diffractive-refractive trifocal IOL with central apodized diffractive rings seems to provide good unaided functional vision for distance, intermediate, and near. The level of patient satisfaction was high. However, a randomized study is required to compare this new trifocal IOL with others on the market.

Table 1. National Eye Institute Visual Functioning Questionnaire (N = 50).

VFQ-25 Item	Score					
	1 (No Problem)	2 (Mild)	3 (Moderate)	4 (Severe)	5 (Bad)	6 (NA)
Glare/flare (trouble seeing street signs due to bright light or oncoming headlight?)	27	20	2	1	—	—
Night vision	49	1	—	—	—	—
Color perception (trouble recognizing specific colors)	50	—	—	—	—	—
Halos (rings around lights)	20	28	1	1	—	—
Depth perception (trouble lining things up, pouring liquids, or going down stairs)	50	—	—	—	—	—
Distorted near vision (straight lines looked crooked close up)	50	—	—	—	—	—
Distorted distance vision (straight lines looked crooked at distance)	50	—	—	—	—	—
Blurred near vision	49	1	—	—	—	—
Blurred far vision	50	—	—	—	—	—
Double vision	49	1 (?)	—	—	—	—
Playing or working outside	50	—	—	—	—	—
Caring for/playing with children	50	—	—	—	—	—
Reading the time on an alarm clock	48	2	—	—	—	—
Seeing clearly when you wake up	46	4	—	—	—	—
Reading the time on a wall clock	50	—	—	—	—	—
Performing your job/hobbies	48	2	—	—	—	—
Participating in sports/recreation	50	—	—	—	—	—
Participating in social events	50	—	—	—	—	—
Reading and near work activities	48	2	—	—	—	—
Driving at night	30	18	2	—	—	—
Driving when it is raining	48	2	—	—	—	—
Using a computer	46	2	2	—	—	—
Cooking	50	—	—	—	—	—
Shopping	50	—	—	—	—	—
Watching TV or movies	48	2	—	—	—	—

NA = not applicable; VFQ = Visual Functioning Questionnaire

WHAT WAS KNOWN

- Traditional bifocal intraocular lenses (IOLs) provide good distance and intermediate vision but lack intermediate vision.
- Trifocal IOLs provide good functional distance, intermediate, and near vision, thereby providing greater spectacle independence.

WHAT THIS PAPER ADDS

- A new design of a hydrophilic diffractive–refractive trifocal IOL seemed to provide good functional vision across all distances.
- The centralized apodized diffractive rings seemed to reduce patients' symptoms of postoperative glare and halos while providing a high level of patient satisfaction.

REFERENCES

- European Commission. EUROSTAT, Statistics Explained. Surgical operations and procedures statistics, 2018
- De Silva SR, Evans JR, Kirithi V, Ziaei M, Leyland M. Multifocal versus monofocal intraocular lenses after cataract extraction. *Cochrane Database Syst Rev* (issue 12):CD003169
- Alfonso JF, Fernández-Vega L, Puchades C, Montés-Micó R. Intermediate visual function with different multifocal intraocular lens models. *J Cataract Refract Surg* 2010; 36:733–739
- Kohnen T, Nuijts R, Levy P, Haefliger E, Alfonso JF. Visual function after bilateral implantation of apodized diffractive aspheric multifocal intraocular lenses with a 3.0 D addition. *J Cataract Refract Surg* 2009; 35:2062–2069
- Gatinel D, Houbrechts Y. Comparison of bifocal and trifocal diffractive and refractive intraocular lenses using an optical bench. *J Cataract Refract Surg* 2013; 39:1093–1099
- Madrid-Costa D, Ruiz-Alcocer J, Ferrer-Blasco T, García-Lázaro S, Montés-Micó R. Optical quality differences between three multifocal intraocular lenses: bifocal low add, bifocal moderate add, and trifocal. *J Refract Surg* 2013; 29:749–754
- Mojzis P, Peña-García P, Liehneova I, Ziak P, Alió JL. Outcomes of a new diffractive trifocal intraocular lens. *J Cataract Refract Surg* 2014; 40:60–69
- Gatinel D, Pagnouille C, Houbrechts Y, Gobin L. Design and qualification of a diffractive trifocal optical profile for intraocular lenses. *J Cataract Refract Surg* 2011; 37:2060–2067
- Cochener B, Vryghem J, Rozot P, Lesieur G, Chevalier J-P, Henry J-M, David T, Lesueur L, Gatinel D, Ganem C, Blanckaert J, Van Acker E, Heireman S, Ghekiere S. Clinical outcomes with a trifocal intraocular lens: a multicenter study. *J Refract Surg* 2014; 30:762–768
- Vryghem JC, Heireman S. Visual performance after the implantation of a new trifocal intraocular lens. *Clin Ophthalmol* 2013; 7:1957–1965
- Alió JL, Plaza-Puche AB, Piñero DP, Amparo F, Rodríguez-Prats JL, Ayala MJ. Quality of life evaluation after implantation of 2 multifocal intraocular lens models and a monofocal model. *J Cataract Refract Surg* 2011; 37:638–648
- McDonnell PJ, Lee P, Spritzer K, Lindblad AS, Hays RD. Associations of presbyopia with vision-targeted health-related quality of life. *Arch Ophthalmol* 2003; 121:1577–1581
- Hoffer KJ, Savini G. Multifocal intraocular lenses: historical perspective. In: Alió JL, Pikkel J, eds. *Multifocal Intraocular Lenses; the Art and the Practice*. Cham, Switzerland, Springer International, 2014; 5–28
- Davison JA, Simpson MJ. History and development of the apodized diffractive intraocular lens. *J Cataract Refract Surg* 2006; 32:849–858
- Cochener B, Lafuma A, Khoshnood B, Courouve L, Berdeaux G. Comparison of outcomes with multifocal intraocular lenses: a meta-analysis. *Clin Ophthalmol* 2011; 5:45–56
- de Vries NE, Nuijts RMMA. Multifocal intraocular lenses in cataract surgery: Literature review of benefits and side effects. *J Cataract Refract Surg* 2013; 39:268–278
- Mendicute J, Kapp A, Lévy P, Krommes G, Arias-Puente A, Tomalla M, Barraquer E, Rozot P, Bouchut P. Evaluation of visual outcomes and patient satisfaction after implantation of a diffractive trifocal intraocular lens. *J Cataract Refract Surg* 2016; 42:203–210
- Bilbao-Calabuig R, Llovet-Rausell A, Ortega-Usobiaga J, Martínez-Del-Pozo M, Mayordomo-Cerdá F, Segura-Albentosa C, Baviera J, Llovet-Osuna F. Visual outcomes following bilateral implantation of two diffractive trifocal intraocular lenses in 10 084 eyes. *Am J Ophthalmol* 2017; 179:55–66
- Kim M, Kim J-h, Lim T-H, Cho BJ. Comparison of reading speed after bilateral bifocal and trifocal intraocular lens implantation. *Korean J Ophthalmol* 2018; 32:77–82
- Lee S, Choi M, Xu Z, Zhao Z, Alexander E, Liu Y. Optical bench performance of a novel trifocal intraocular lens compared with a multifocal intraocular lens. *Clin Ophthalmol* 2016; 10:1031–1038
- Kohnen T, Titke C, Böhm M. Trifocal intraocular lens implantation to treat visual demands in various distances following lens removal. *Am J Ophthalmol* 2016; 161:71–77
- Jonker SMR, Bauer NJC, Makhotkina NY, Berendschot TTJM, van den Biggelaar FJHM, Nuijts RMMA. Comparison of a trifocal intraocular lens with a +3.0 D bifocal IOL: results of a prospective randomized clinical trial. *J Cataract Refract Surg* 2015; 41:1631–1640; erratum, 2017; 43:148–150
- Reinstein DZ, Archer TJ, Srinivasan S, Mamalis N, Kohnen T, Dupps WJ Jr, Randleman JB. Standard for reporting refractive outcomes of intraocular lens-based refractive surgery [editorial]. *J Cataract Refract Surg* 2017; 43:435–439
- Alió JL, Plaza-Puche AB, Alió del Barrio JL, Amat-Peral P, Ortuño V, Yébanes P, Al-Shymali O, Vega-Estrada A. Clinical outcomes with a diffractive trifocal intraocular lens. *Eur J Ophthalmol* 2018; 28:419–424
- Kohnen T, Herzog M, Hemkeppeler E, Schönbrunn S, De Lorenzo N, Petermann K, Böhm M. Visual performance of a quadrifocal (trifocal) intraocular lens following removal of the crystalline lens. *Am J Ophthalmol* 2017; 184:52–62
- Fernández J, Rodríguez-Vallejo M, Martínez J, Tauste A, Piñero DP. Biometric factors associated with the visual performance of a high addition multifocal intraocular lens. *Curr Eye Res* 2018; 43:998–1005
- Alió JL, Kaymak H, Breyer D, Cochener B, Plaza-Puche AB. Quality of life related variables measured for three multifocal diffractive intraocular lenses: a prospective randomised clinical trial. *Clin Exp Ophthalmol* 2018; 46:380–388

OTHER CITED MATERIAL

- Medicontur Medical Engineering Ltd., Inc. Medicontur IOL Optimizer With New Toric IOL Calculator. Available at: <https://toriccalculator.net/#/main>. Accessed February 25, 2019
- National Eye Institute Visual Functioning Questionnaire – 25 (VFQ-25) version 2000. (Self-Administered Format). Available at: https://nei.nih.gov/sites/default/files/nei-pdfs/vfq_sa.pdf. Accessed February 25, 2019

Disclosures: None of the authors has a financial or proprietary interest in any material or method mentioned.



First author:

Jozsef F. Gyory, MD

Department of Ophthalmology, Csolnoky
Ferenc Hospital, Veszprem, Hungary